

Case report

Fatal breakthrough mucormycosis in a multivisceral transplant patient receiving micafungin: Case report and literature review



John R. Louis-Auguste^{a,*}, Christianne Micallef^b, Tim Ambrose^c, Sara Upponi^d, Andrew J. Butler^e, Dunecan Massey^c, Stephen J. Middleton^c, Neil Russell^e, Charlotte S. Rutter^f, Lisa M. Sharkey^c, Jeremy Woodward^c, Effrossyni Gkrania-Klotsas^g, David A. Enoch^b

^a Department of Gastroenterology, St George's University Hospitals NHS Foundation Trust, London, UK

^b Clinical Microbiology & Public Health Laboratory, Cambridge University Hospitals NHS Foundation Trust, Cambridge, UK

^c Department of Gastroenterology, Cambridge University Hospitals NHS Foundation Trust, Cambridge, UK

^d Department of Radiology, Cambridge University Hospitals NHS Foundation Trust, Cambridge, UK

^e Department of Surgery, Cambridge University Hospitals NHS Foundation Trust, Cambridge, UK

^f Department of Gastroenterology, University Hospital Southampton NHS Foundation Trust, Southampton, UK

^g Department of Infectious Diseases, Cambridge University Hospitals NHS Foundation Trust, Cambridge, UK

ARTICLE INFO

Keywords:

Antifungal therapy
Micafungin
Mucormycosis
Multivisceral transplantation
Immunosuppression
Fungal infection

ABSTRACT

Introduction: Antifungal agents are routinely used in the post-transplant setting for both prophylaxis and treatment of presumed and proven fungal infections. Micafungin is an echinocandin-class antifungal with broad antifungal cover and favorable side effect profile but, notably, it has no activity against molds of the order Mucorales.

Presentation of case: A 47-year-old woman underwent multivisceral transplantation for intestinal failure-associated liver disease. She had a prolonged post-operative recovery complicated by invasive candidiasis and developed an intolerance to liposomal amphotericin B. In view of her immunosuppression, she was commenced on micafungin as prophylaxis to prevent invasive fungal infection. However, she developed acute graft versus host disease with bone marrow failure complicated by disseminated mucormycosis which was only diagnosed post mortem.

Discussion: Non-*Aspergillus* breakthrough mold infections with micafungin therapy are rare with only eight other cases having been described in the literature. Breakthrough infections have occurred within one week of starting micafungin. Diagnosis is problematic and requires a high degree of clinical suspicion and microscopic/histological examination of an involved site. The management of these aggressive infections involves extensive debridement and appropriate antifungal cover.

Conclusion: A high level of suspicion of invasive fungal infection is required at all times in immunosuppressed patients, even those receiving antifungal prophylaxis. Early biopsy is required. Even with early recognition and aggressive treatment of these infections, prognosis is poor.

Introduction

Solid organ transplant recipients are at risk of opportunistic bacterial, viral, parasitic and fungal infections. Broad spectrum antimicrobial agents are often used for prophylaxis and treatment of opportunistic infections post-transplant.

Micafungin is a broad spectrum echinocandin class antifungal agent. Echinocandins uniquely target the fungal cell wall, giving them a favorable side effect profile. Micafungin has potent in vitro and in vivo

activity against all major *Candida* species, *Aspergillus* species and less common pathogens such as *Paecilomyces* and *Penicillium*. However, it has no activity against *Cryptococcus* spp. and members of the order Mucorales.

Breakthrough infections are a recognized complication of therapy with any antimicrobial agent, but are an uncommon feature of micafungin use. Here we present a case and review the literature of all breakthrough non-*Aspergillus* mold infections described with the use of micafungin.

Abbreviations: bd, twice daily; CMV, cytomegalovirus; CT, computed tomography scan; GvHD, graft-versus-host disease; L-AmB, liposomal amphotericin B; MIC, minimum inhibitory concentration; od, once daily; spp., species

* Corresponding author.

E-mail address: j.louis-auguste@nhs.net (J.R. Louis-Auguste).

<https://doi.org/10.1016/j.idcr.2018.03.017>

Case

A 47-year-old woman with cirrhosis due to intestinal failure associated liver disease was referred for multivisceral transplantation. Multiple small bowel resections due to visceral myopathy resulted in short bowel syndrome, small intestinal bacterial overgrowth and gastrointestinal dysmotility. A liver biopsy after four years of parenteral nutrition confirmed advanced cirrhosis and multivisceral transplantation (stomach, liver, pancreas, small bowel and colon) was indicated.

Both donor and recipient were cytomegalovirus (CMV) IgG negative. Induction immunosuppression consisted of methylprednisolone followed by alemtuzumab (anti-CD52). Maintenance immunosuppression initially consisted of a reducing course of prednisolone and tacrolimus. Tacrolimus was replaced by cyclosporine on day 40 due to posterior reversible encephalopathy syndrome.

Initial recipient antimicrobial prophylaxis consisted of meropenem, vancomycin, liposomal amphotericin B (L-AmB) 1 mg/kg od, co-trimoxazole 480 mg three times a week and acyclovir, as per our institutional protocol. On day 3 *Candida glabrata* was isolated from blood cultures and drain fluid. The dose of L-AmB was increased to 3 mg/kg/day. This was switched to voriconazole after she developed a cutaneous drug reaction.

Through her admission there was a prolonged period of pyrexia and intermittent bacteremia. Positive blood cultures included enterococci, *Elizabethkingia meningoseptica*, *Staphylococcus haemolyticus*, and *Escherichia coli*, but there was no fungemia. Voriconazole was switched to micafungin 100 mg od due to low serum voriconazole levels (secondary to drug interactions) on day 96, which was subsequently increased to 100 mg bd due to lack of clinical response.

On day 79 a diffuse maculopapular rash was noted. Skin biopsy demonstrated graft-versus-host disease (GvHD), confirmed by fluorescence in situ hybridization analysis. Peripheral blood chimerism analysis demonstrated 96% donor-positive lymphocytes. She suffered from rapid and irreversible bone marrow failure from day 90 which required frequent red cell and platelet transfusions. Bone marrow examination was acellular, consistent with GvHD. Immunosuppression was initially increased with further doses of high-dose methylprednisolone, basiliximab (anti-IL-2), and alemtuzumab with no response. Immunosuppression was withdrawn on day 120, again with no response. A haplo-identical bone marrow transplant from a relative was planned for day 168.

A granulocyte infusion was given as bridging therapy to control the sepsis pending bone marrow transplant on day 164 which was associated with a platelet increment to $> 130 \times 10^9/L$. She was also noted to have developed dysarthria with unilateral isolated upper motor neurone facial nerve palsy prior to the infusion. Cranial computed tomography scan (CT) (performed after the granulocyte infusion) confirmed an acute frontal infarct. Over the next 24 h she deteriorated rapidly and was transferred to the intensive care unit. Repeat CT of head, chest, abdomen and pelvis (Fig. 1) revealed extensive and catastrophic infarcts involving both kidneys, bowel and liver, a large new cerebral infarct, and extension of her established cerebral infarct with hemorrhagic transformation and significant edema and midline shift. Treatment was withdrawn and she died soon after.

Post mortem examination revealed extensive invasive mucormycosis diagnosed histopathologically, affecting the vasculature as well as parenchyma of her lungs, brain, heart and liver, and a left ventricular fungal thrombus. Following discontinuation of L-AmB and voriconazole, she received micafungin for a total of 69 days. There had been no time without antifungal coverage. Apart from the early *Candida* isolates, fungal cultures and serum galactomannan levels had been negative throughout her illness.

Methods

PubMed was searched using the search string '(micafungin AND

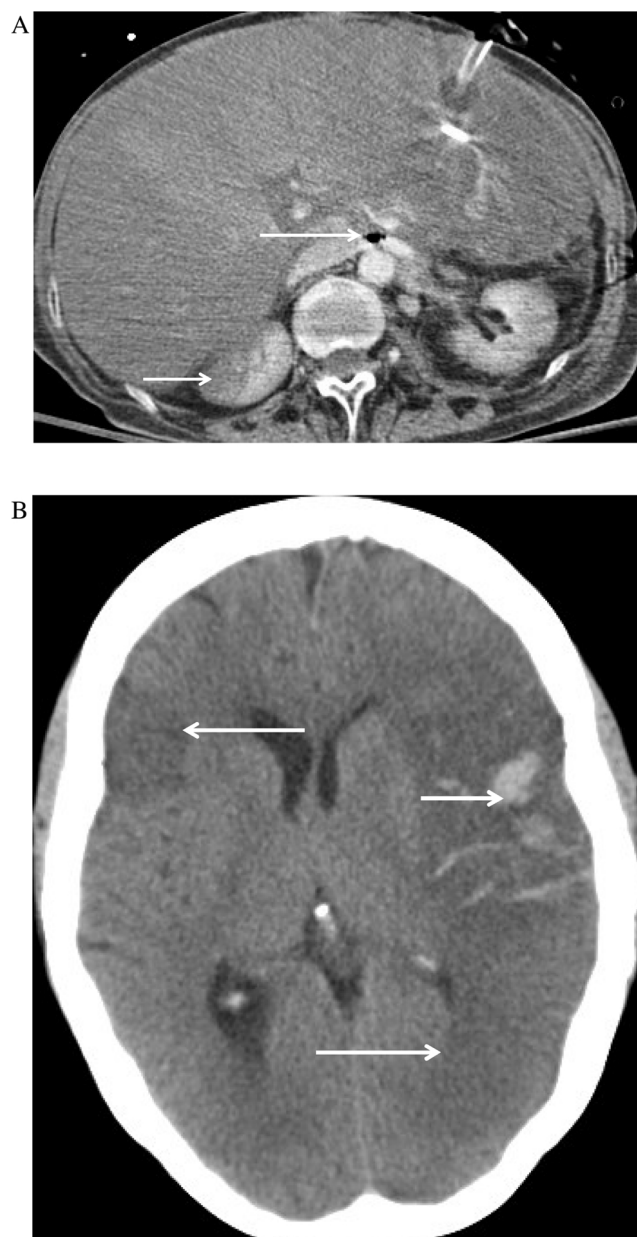


Fig. 1. A. CT abdomen at day 165 showing poor enhancement of the liver with heterogeneous attenuation of the right lobe, gas in the left renal vein (long arrow) and infarcts in the right kidney (short arrow). B. CT head at day 165 showing extensive bilateral cerebral infarction (long arrows), left fronto-parietal hemorrhage (short arrow) and mass effect within the left cerebral hemisphere.

Aspergillus breakthrough [Title/Abstract] OR (micafungin AND rhizopus [Title/Abstract]) OR (micafungin AND zygomycetes) OR (micafungin AND Mucor [Title/Abstract]) OR (micafungin AND Rhizopus [Title/Abstract]) OR (micafungin AND Absidia [Title/Abstract]) OR (Cunninghamella AND micafungin [Title/Abstract]) OR (Rhizomucor AND micafungin [Title/Abstract]) OR (Lichtheimia AND micafungin [Title/Abstract]) OR (Apophysomyces AND micafungin [Title/Abstract]) OR (Basidiobolus AND micafungin [Title/Abstract]) OR (Conidiobolus AND micafungin [Title/Abstract]), OR (Scedosporium AND micafungin [Title/Abstract]) OR (Fusarium AND micafungin [Title/Abstract]) and the articles cited therein in articles written in English for the period January 1997 to December 2017.

Three authors (DE, CM & JLA) then read the articles and included all clinical cases of breakthrough infection with molds whilst the

patient was receiving micafungin.

Discussion

Invasive fungal infections are known to occur in over 10% of intestinal transplant recipients in recent series [1]. In solid organ transplant recipients in general, the majority of fungal infections are due to *Candida* or *Aspergillus* [1], for which both amphotericin B and micafungin provide adequate coverage. In this case micafungin was chosen to provide prophylaxis while she was neutropenic, due to her intolerance to amphotericin B and interactions with voriconazole, though this is not a licensed indication [2]. It is likely that *Mucor* was selected by micafungin use.

Mucor is a genus of opportunistic environmental molds which classically causes angioinvasive infections in immunocompromised patients. Mucormycosis is frequently fatal even with prompt diagnosis, appropriate therapy and aggressive debridement [3]. Diagnosis requires a high degree of clinical suspicion and often requires histopathological examination and culture of involved tissue, as routine cultures are often negative [3]. Amphotericin B has the best evidence base, although isavuconazole and posaconazole are alternatives [4,5]. Although monotherapy is not a therapeutic option, micafungin may be considered as add-on therapy due to synergistic properties [6]. Micafungin has limited in vitro activity [i.e. minimum inhibitory concentration [MIC] > 4 mg/L] against the mucoraceous molds, *Fusarium solani*, *Pseudallescheria boydii* and molds with holoblastic conidia (e.g. *Aureobasidium* spp. and *Alternaria* spp.) [7]. Susceptibility data should therefore ideally be obtained before starting therapy [8].

Breakthrough infections due to non-*Aspergillus* molds on micafungin remain rare (Table 1), with only nine other cases previously reported [9–14]. Other than three case reports, six cases were identified during the course of clinical trials involving almost 700 neutropenic patients receiving micafungin for treatment [10] or prophylaxis [9,14]. Of the eight patients for whom information is available, seven were receiving immunosuppressive therapy; the other was diabetic. Exposure to micafungin varied from 6 days to > 3 months. Conversely, several large multicenter studies of patients receiving micafungin have been published, predominantly from Japan which showed no breakthrough infections due to these molds [15–20].

Positive fungal culture or histology remains the gold standard for diagnosis. Serological markers [e.g. β -D glucan/galactomannan] are often negative even in overwhelming infection [12]. One of the recognized limitations of β -D glucan is that it remains negative in patients with infections due to mucormycetes and *Cryptococcus* [2], whilst galactomannan, a constituent of the cell wall of *Aspergillus* and *Penicillium* should also remain negative as it's not a component of these fungi. Clinical features were non-specific in all cases and were catastrophic in ours.

In conclusion, non-*Aspergillus* non-*Candida* breakthrough infections can occur within two weeks of starting micafungin and usually occur in immunocompromised hosts. A high clinical index of suspicion is required due to a non-specific presentation. Clinicians should be aware of the limitations of antifungal use generally and the limitations of current screening and diagnostic testing algorithms for detecting fungal infections in immunosuppressed individuals. Early biopsy is therefore the most useful investigation in these patients. Unfortunately, even with prompt recognition and aggressive surgical and antimicrobial therapy, these infections are often fatal.

Contributions

JR Louis-Auguste: Concept and design of the paper; performed literature search; drafted and revised the manuscript.

C Micallef: Concept and design of the paper; performed literature search; drafted and revised the manuscript.

T Ambrose: Concept and design of the paper; revised the

Table 1 Mold breakthrough cases during micafungin therapy [other than *Aspergillus* spp.]

Ref.	Year	Country	n	Organism	Method of identification	Age/sex	Underlying condition	BDG	Immuno-suppression	Site of infection	Daily dose [mg]	Duration of therapy [total dose]	Outcome
This case	2014	UK	1	Mucormycetes	Histology – post mortem	47/F	MVT, GvHD, visceral myopathy	N/A	MMF, CYA, steroids	lung, brain, heart, liver	100–200	69d [10500 mg]	Died
[12]	2009	Japan	1	Mucormycetes	Histology – post mortem	69/M	AML, DM	Neg	DA, Prednisolone	bowel	150	13d [1950 mg]	Died
[9]	2004	USA	1	Mucormycetes	u/k	u/k	HSCt	u/k	u/k	u/k	50	u/k	u/k
[10]	2010	USA	1	Mucormycetes	u/k	u/k	Febrile neutropenia	u/k	u/k	u/k	100	u/k	u/k
[14]	2015	Austria	1	Mucormycetes	u/k	u/k	Acute leukemia	u/k	u/k	lung	50	16d [800 mg]	u/k
[14]	2015	Austria	1	<i>Lichtheimia corymbifera</i>	Histology – post mortem	u/k	Acute leukemia	u/k	u/k	Lung, skin, brain	50	6d [300 mg]	Died
[14]	2015	Austria	1	<i>Aureobasidium</i> spp.	u/k	u/k	Acute leukemia	u/k	u/k	Soft tissue	50	24d [1200 mg]	u/k
[14]	2015	Austria	1	<i>Hormoglyphella aspergillata</i>	u/k	u/k	Acute leukemia	u/k	u/k	Lung, skin	50	30d [1500 mg]	u/k
[11]	2013	Japan	1	<i>Scedosporium aurantiacum</i>	Culture	68/F	DM	Pos	Nil	lung, brain	150	16d [2400 mg]	Survived
[13]	2014	Japan	1	<i>Scedosporium prolificans</i>	Culture	35/M	Renal transplant	Pos	MMF, steroids, Tac	lung, brain, heart valve, blood	150	> 3 months	Died

Key: AML: acute myeloid leukemia; BDG: β -D-glucan; CYA: cyclosporine; d: days; DA: cytarabine – daunarubicin; DM: diabetes mellitus; F: female; GvHD: graft versus host disease; HSCt: hemopoietic stem cell transplant; M: male; MMF: mycophenolate mofetil; MVT: multivisceral transplant; N/A: not applicable; Neg: negative; Pos: positive; Tac: Tacrolimus; u/k: unknown; UK: United Kingdom USA: United States of America.

manuscript.

S Upponi: Revised the manuscript; provided and interpreted radiological images.

AJ Butler: Concept and design of the paper; revised the manuscript.

D Massey: Concept and design of the paper; revised the manuscript.

SJ Middleton: Concept and design of the paper; revised the manuscript.

N Russell: Concept and design of the paper; revised the manuscript.

CS Rutter: Concept and design of the paper; revised the manuscript.

LM Sharkey: Concept and design of the paper; revised the manuscript.

J Woodward: Concept and design of the paper; revised the manuscript.

E Gkrania-Klotsas: Concept and design of the paper; revised the manuscript.

DA Enoch: Concept and design of the paper; performed literature search; drafted and revised the manuscript.

Consent

Written informed consent was obtained from the patient's next of kin for publication of this case report and accompanying images. A copy of the written consent is available for review by the Editor-in-Chief of this journal on request.

Conflict of interest statement

DAE has received funding to attend conferences from MSD, Gilead and Astellas. CR has received funding from Norgine, Shire and Astellas to attend scientific conferences; Dr Falk and Shire for invited presentations; Nutricia for sponsorship of local educational courses. All other authors declare no conflicts of interest.

Funding

None.

Acknowledgement

None.

References

- [1] Primeggia J, Matsumoto CS, Fishbein TM, Karacki PS, Fredette TM, Timpone JG. Infection among adult small bowel and multivisceral transplant recipients in the 30-day postoperative period. *Transpl Infect Dis* 2013;15(5):441–8. <http://dx.doi.org/10.1111/tid.12107>.
- [2] Enoch DA, Idris S, Micallef C, Sule O, Karas J. Micafungin for the treatment of invasive aspergillosis. *J Infect* 2014;68(6):507–26.
- [3] Prabhu RM, Patel R. Mucormycosis and entomophthoromycosis: a review of the clinical manifestations, diagnosis and treatment. *Clin Microbiol Infect* 2004;10:31–47. <http://dx.doi.org/10.1111/j.1470-9465.2004.00843.x>.
- [4] Enoch DA, Aliyu S, Sule O, Lewis S, Karas J. Posaconazole for the treatment of mucormycosis. *Int J Antimicrob Agents* 2011;38(6):465–73.
- [5] Marty FM, Ostrosky-Zeichner L, Cornely OA, Mullane KM, Perfect JR, Thompson GR, et al. Isavuconazole treatment for mucormycosis: a single-arm open-label trial and case-control analysis. *Lancet Infect Dis* 2016(March). [http://dx.doi.org/10.1016/S1473-3099\(16\)00071-2](http://dx.doi.org/10.1016/S1473-3099(16)00071-2).
- [6] Rodríguez MM, Calvo E, Serena C, Mariné M, Pastor FJ, Guarro J. Effects of double and triple combinations of antifungal drugs in a murine model of disseminated infection by *Scedosporium prolificans*. *Antimicrob Agents Chemother* 2009;53(5):2153–5. <http://dx.doi.org/10.1128/AAC.01477-08>.
- [7] Cuenca-Estrella M, Gomez-Lopez A, Mellado E, Monzon A, Buitrago MJ, Rodriguez-Tudela JL. Activity profile in vitro of micafungin against Spanish clinical isolates of common and emerging species of yeasts and molds. *Antimicrob Agents Chemother* 2009;53(5):2192–5. <http://dx.doi.org/10.1128/AAC.01543-08>.
- [8] Lackner M, de Hoog GS, Verweij PE, Najafzadeh MJ, Curfs-Breuker I, Klaassen CH, et al. Species-specific antifungal susceptibility patterns of *Scedosporium* and *Pseudallescheria* species. *Antimicrob Agents Chemother* 2012;56(5):2635–42. <http://dx.doi.org/10.1128/AAC.05910-11>.
- [9] van Burik J-AH, Ratanatharathorn V, Stepan DE, Miller CB, Lipton JH, Vesole DH, et al. Micafungin versus fluconazole for prophylaxis against invasive fungal infections during neutropenia in patients undergoing hematopoietic stem cell transplantation. *Clin Infect Dis* 2004;39(10):1407–16. <http://dx.doi.org/10.1086/422312>.
- [10] Kubiak DW, Bryar JM, McDonnell AM, Delgado-Flores JO, Mui E, Baden LR, et al. Evaluation of caspofungin or micafungin as empiric antifungal therapy in adult patients with persistent febrile neutropenia: a retrospective, observational, sequential cohort analysis. *Clin Ther* 2010;32(4):637–48. <http://dx.doi.org/10.1016/j.clinthera.2010.04.005>.
- [11] Nakamura Y, Suzuki N, Nakajima Y, Utsumi Y, Murata O, Nagashima H, et al. *Scedosporium aurantiacum* brain abscess after near-drowning in a survivor of a tsunami in Japan. *Respir Investig* 2013;51(4):207–11. <http://dx.doi.org/10.1016/j.resinv.2013.07.001>.
- [12] Suzuki K, Sugawara Y, Sekine T, Nakase K, Katayama N. Breakthrough disseminated zygomycosis induced massive gastrointestinal bleeding in a patient with acute myeloid leukemia receiving micafungin. *J Infect Chemother* 2009;15(1):42–5. <http://dx.doi.org/10.1007/s10156-008-0657-5>.
- [13] Uno K, Kasahara K, Kutsuna S, Katanami Y, Yamamoto Y, Maeda K, et al. Infective endocarditis and meningitis due to *Scedosporium prolificans* in a renal transplant recipient. *J Infect Chemother* 2014;20(2):131–3. <http://dx.doi.org/10.1016/j.jiac.2013.09.006>.
- [14] Nachbar D, Angelova O, Orth-Höller D, Ditzbacher A, Lackner M, Auberger J, et al. Primary antifungal prophylaxis with micafungin in patients with haematological malignancies: real-life data from a retrospective single-centre observational study. *Eur J Haematol* 2015;94(3):258–64. <http://dx.doi.org/10.1111/ejh.12426>.
- [15] Chan TSY, Hwang Y-Y, Gill H, Cheung WWW, Tse E, Leung AYH, et al. Antifungal drug usage in haematologic patients during a 4-year period in an Asian university teaching hospital. *Intern Med J* 2013;43(5):541–6. <http://dx.doi.org/10.1111/imj.12064>.
- [16] Goto N, Hara T, Tsurumi H, Ogawa K, Kitagawa J, Kanemura N, et al. Efficacy and safety of micafungin for treating febrile neutropenia in hematological malignancies. *Am J Hematol* 2010;85(11):872–6. <http://dx.doi.org/10.1002/ajh.21858>.
- [17] Kobayashi R, Suzuki N, Yoshida M, Iizuka S, Suzuki D, Sano H, et al. Efficacy and safety of micafungin for febrile neutropenia in pediatric patients with hematological malignancies: a multicenter prospective study. *J Pediatr Hematol Oncol* 2013;35(7):e276–9. <http://dx.doi.org/10.1097/MPH.0b013e318299c6bd>.
- [18] Vehreschild MJGT, von Bergwelt-Baildon M, Tran L, Shimabukuro-Vornhagen A, Wisplinghoff H, Bangard C, et al. Feasibility and effectiveness of posaconazole prophylaxis in combination with micafungin bridging for patients undergoing allogeneic stem cell transplantation: a 6-yr analysis from the cologne cohort for neutropenic patients. *Eur J Haematol* 2014;93(5):400–6. <http://dx.doi.org/10.1111/ejh.12368>.
- [19] Yamaguchi M, Kurokawa T, Ishiyama K, Aoki G, Ueda M, Matano S, et al. Efficacy and safety of micafungin as an empirical therapy for invasive fungal infections in patients with hematologic disorders: a multicenter, prospective study. *Ann Hematol* 2011;90(10):1209–17. <http://dx.doi.org/10.1007/s00277-011-1277-1>.
- [20] Chan TSY, Gill H, Hwang Y-Y, Sim J, Tse ACT, Loong F, et al. Breakthrough invasive fungal diseases during echinocandin treatment in high-risk hospitalized hematologic patients. *Ann Hematol* 2014;93(3):493–8. <http://dx.doi.org/10.1007/s00277-013-1882-2>.