

Full clinical cases submission template

TITLE OF CASE <i>Do not include "a case report"</i> Levetiracetam-induced eosinophilic pneumonia
SUMMARY <i>Up to 150 words summarising the case presentation and outcome (this will be freely available online)</i> Levetiracetam is widely regarded as a benign anti-epileptic drug, in contrast to older anti-epileptic medication. We report a case of eosinophilic pneumonia due to levetiracetam use in a 59-year old non-smoking woman with no previous respiratory history. Our patient presented with exertional breathlessness and marked desaturation on exertion. She displayed 'reverse bat-wing' infiltrates on her chest radiograph and peripheral eosinophilia on a complete blood count. Her symptoms, radiology and peripheral eosinophilia resolved completely with cessation of levetiracetam and a course of prednisolone. This is the first report of isolated eosinophilic pneumonia due to levetiracetam. Other reports of levetiracetam-induced eosinophilia describe drug rash, eosinophilia, and systemic symptoms (DRESS syndrome). Detection of pulmonary drug reactions requires a careful drug history and high index of suspicion. Identifying and reporting a causative agent is crucially important, as cessation of the drug is essential for resolution of the syndrome.
BACKGROUND <i>Why you think this case is important – why did you write it up?</i> Levetiracetam is a relatively recently introduced anti-epileptic drug which functions by binding to synaptic vesicle protein (SV2A), thus reducing the rate of vesicle release ¹ . It has been recommended by NICE as an alternative first-line treatment in focal and myoclonic seizures, as well as an adjunctive treatment for focal, generalised tonic clonic and myoclonic seizures ² . Levetiracetam is growing in popularity as it is widely regarded as a benign anti-epileptic with comparatively few side effects and interactions, particularly when compared to older drugs such as carbamazepine. For example, levetiracetam is linked to cutaneous reactions in approximately 1.7% of patients compared to 5-15% for phenytoin, carbamazepine, and phenobarbitone; and 8.3-20% for lamotrigine ³⁻⁵ . Levetiracetam also appears to have a far lower incidence of the rarer but potentially very dangerous idiosyncratic reactions such as agranulocytosis and aplastic anaemia (carbamazepine, phenytoin), pancreatitis (carbamazepine, phenytoin), and hepatic failure (valproate, carbamazepine, phenytoin). Direct comparisons are difficult as levetiracetam was launched recently, and there are few blinded randomized control trials comparing anti-epileptics. This is the first known report of isolated eosinophilic pneumonia secondary to levetiracetam.

BMJ Case Reports

CASE PRESENTATION <i>Presenting features, medical/social/family history</i>
<p>A 59-year old non-smoking female presented with several weeks of exertional breathlessness and night sweats. She had been recently diagnosed with a meningioma and linked her symptoms to starting levetiracetam 8 weeks prior (as treatment for meningioma-related absence seizures). She did not have a cough, chest pain or any other previous medical history. Her physical examination was unremarkable other than peripheral oxygen saturations which dropped from 95% to 88% on exercise. There was no wheeze, rash, lymphadenopathy or angioedema.</p>
INVESTIGATIONS <i>If relevant</i>
<p>New eosinophilia ($8.38 \times 10^9/L$) was the only abnormality on blood tests. Her chest radiograph (Fig. 1AI) showed ‘reverse bat-wing’ infiltrates in an asymmetrical pattern (more marked on the right). Computed-tomography showed peripheral areas of consolidation (Fig. 1B).</p>
DIFFERENTIAL DIAGNOSIS <i>If relevant</i>
<p>Eosinophilia can be defined as a raised eosinophil count of $\geq 0.5 \times 10^9/L$, with hypereosinophilia indicating severe eosinophilia ($\geq 1.5 \times 10^9/L$) and hypereosinophilic syndrome describing hypereosinophilia occurring on at least 2 occasions with end-organ damage attributable to the eosinophilia. Eosinophilic pneumonias are a heterogeneous group of disorders characterised by eosinophilia and pulmonary infiltrates. In eosinophilic pneumonias, the eosinophilia can affect the peripheral blood and the lungs or be limited to the lungs. Eosinophilic pneumonias can be part of an underlying disorder (such as allergic broncho-pulmonary aspergillosis, autoimmune disorders e.g. eosinophilic granulomatosis with polyangiitis, infections, particularly of a parasitic nature, and malignancy) or they can primarily affect the lungs (acute eosinophilic pneumonia, chronic eosinophilic pneumonia, and drug-induced eosinophilic pneumonia).</p> <p>Our patient was a life-long resident of the United Kingdom with no recent travel history or symptoms to suggest parasitic infection. There was no history of weight loss, lymphadenopathy or any other abnormality in the full blood count (aside from eosinophilia) that would suggest an underlying malignancy. Levetiracetam was the only drug that had been recently started and our patient denied any over-the-counter medications or herbal supplements. The combination of temporally-linked symptoms, eosinophilia and suggestive radiology was felt to be highly characteristic of a drug reaction and therefore tissue biopsy was not sought.</p>

BMJ Case Reports

TREATMENT *If relevant*

Our patient was reasonably well, her eosinophilic pneumonia appeared to be clearly driven by the levetiracetam and she had a good support network at home. Therefore we felt that outpatient treatment was appropriate. The levetiracetam was stopped. As she had previously experienced meningioma-related seizures she was discussed with the neurosurgeons. Phenytoin was prescribed as a replacement anti-epileptic. As there was evidence of end-organ dysfunction (in the form of exertional desaturation) she was treated with a course of prednisolone, which was tapered off gradually over the next two months.

OUTCOME AND FOLLOW-UP

The patient was followed-up 12 days later. She had clinically improved but still had low-level eosinophilia ($1.28 \times 10^9/L$). One month later her chest radiograph and eosinophil count (Fig.1AIII, 1C) had normalised and she was symptom-free.

DISCUSSION *Include a very brief review of similar published cases*

The original clinical trials of levetiracetam reported accidental injury, asthenia, dizziness, headache, infection, nausea and somnolence as primary adverse reactions⁶. Interestingly none of them occurred more frequently than in placebo arms. Since then the most commonly reported side effects of levetiracetam are neuropsychiatric (in approximately 13% of adult patients); ranging from dizziness, somnolence, depression and hostility, to frank psychosis⁷. This is the first report of 'stand-alone' eosinophilic pneumonia due to levetiracetam. Other reports of levetiracetam-induced eosinophilic syndromes describe drug rash, eosinophilia, and systemic symptoms (DRESS syndrome) with concomitant pulmonary infiltrates⁸⁻¹¹.

Antiepileptic drugs, in particular carbamazepine, phenytoin and phenobarbital, are the most common causes of drug-induced eosinophilia and DRESS; but allopurinol, antibiotics (especially sulphonamides), anti-malarials and NSAIDs have also been implicated¹². DRESS is a delayed T-cell mediated reaction and several causes have been proposed, including a genetic deficiency of drug-metabolizing enzymes, associations with specific human leucocyte antigens (HLAs) and possible reactivation of latent herpes viruses through drug-virus interactions¹³. Cross-reactions between phenytoin, carbamazepine, phenobarbitone and oxcarbazepine are common as they share a similar 'aromatic' structure¹⁴. Levetiracetam has a different structure, which may account for the low-incidence of cross-reactivity with other anti-epileptics.

BMJ Case Reports

Detection of pulmonary drug reactions and DRESS requires a careful history and high index of suspicion. The RegiSCAR scoring system has recently been developed to report and grade suspected DRESS cases as being ‘unlikely to be drug-associated’, ‘possible’, ‘probable’, or ‘definite’¹⁵. Prompt recognition is crucial as the mortality associated with DRESS approaches 10%¹². Both pulmonary drug reactions and DRESS syndrome are managed by withdrawal of the offending agent and careful supportive treatment¹⁶. Corticosteroids are frequently used but evidence is limited. Helpful resources for information on drug-induced respiratory disease include the Pneumotox website¹⁷ and the U.S. Food and Drug Administration Medwatch programme¹⁸. The former is particularly user-friendly as it allows searching the database by individual drug names as well as by patterns of pulmonary disease. Reporting of drug reactions is critical to allow clinicians a complete view of the risk/benefit balance prior to recommending specific medications.

LEARNING POINTS/TAKE HOME MESSAGES *3 to 5 bullet points – this is a required field*

1. New eosinophilia ($>0.5 \times 10^9/L$ or 3% of leucocytes) should always raise the possibility of drug-induced syndromes.
2. Detection of pulmonary drug reactions requires a careful history and high index of suspicion. The physician should enquire not only about prescribed medications but also over-the-counter remedies, herbal supplements and illicit drug use.
3. Identifying and reporting a causative agent is important, as cessation of the agent is crucial for resolution of the pulmonary syndrome.

REFERENCES *Vancouver style (Was the patient involved in a clinical trial? Please reference related articles)*

1. Lynch B, Lambeng N, Nocka K, Kensel-Hammes P, Bajjalieh S, Matagne A et al. The synaptic vesicle protein SV2A is the binding site for the antiepileptic drug levetiracetam. *Proceedings of the National Academy of Sciences*. 2004;101(26):9861-9866.
2. Epilepsies: diagnosis and management [Internet]. Nice.org.uk. 2012 [cited 29 January 2017]. Available from: <https://www.nice.org.uk/guidance/cg137/chapter/About-this-guideline>
3. Błaszczyk B, Lasoń W, Czuczwar S. Antiepileptic drugs and adverse skin reactions: An update. *Pharmacological Reports*. 2015;67(3):426-434.
4. Wang X, Lang S, Shi X, Tian H, Wang R, Yang F. Antiepileptic drug-induced skin reactions: A retrospective study and analysis in 3793 Chinese patients with epilepsy. *Clinical Neurology and Neurosurgery*. 2012;114(7):862-865.
5. Anderson G. Children Versus Adults: Pharmacokinetic and Adverse-Effect Differences.

- Epilepsia. 2002;43:53-59.
6. Welty T, Gidal B, Ficker D, Privitera M. Levetiracetam: A Different Approach to the Pharmacotherapy of Epilepsy. *The Annals of Pharmacotherapy*. 2002;36:296-304.
 7. Wade J, Dang C, Nelson L, Wasserberger J. Emergent Complications of the Newer Anticonvulsants. *The Journal of Emergency Medicine*. 2010;38(2):231-237.
 8. Gómez-Zorrilla S, Ferraz A, Pedrós C, Lemus M, Peña C. Levetiracetam-Induced Drug Reaction with Eosinophilia and Systemic Symptoms Syndrome. *Annals of Pharmacotherapy*. 2012;46(7-8):e20-e20.
 9. Flannery A, Willey M, Thompson Bastin M, Buch K, Bensadoun E. Eosinophilia and Fever with Levetiracetam: A Case Report. *Pharmacotherapy: The Journal of Human Pharmacology and Drug Therapy*. 2015;35(8):e131-e135.
 10. Dar W, Sofi N, Latief M, Dar I, Kasana B. Levetiracetam induced drug reaction with eosinophilia and systemic symptom syndrome. *Indian Journal of Dermatology*. 2016;61(2):235.
 11. Bayram A, Canpolat M, Çınar S, Tahan F, Gumus H, Kumandaş S et al. Drug Reaction with Eosinophilia and Systemic Symptoms Syndrome Induced by Levetiracetam in a Pediatric Patient. *The Journal of Emergency Medicine*. 2016;50(2):e61-e66.
 12. Choudhary S, McLeod M, Torchia D, Romanelli P. Drug Reaction with Eosinophilia and Systemic Symptoms (DRESS) Syndrome. *The Journal of clinical and aesthetic dermatology*. 2013;6(6):31.
 13. Cacoub P, Musette P, Descamps V, Meyer O, Speirs C, Finzi L et al. The DRESS Syndrome: A Literature Review. *The American Journal of Medicine*. 2011;124(7):588-597.
 14. Romano A, Pettinato R, Andriolo M, Viola M, Gueant-Rodriguez R, Luigi Valluzzi R et al. Hypersensitivity to Aromatic Anticonvulsants: In Vivo and In Vitro Cross-Reactivity Studies. *Current Pharmaceutical Design*. 2006;12(26):3373-3381.
 15. RegiSCAR [Internet]. Regiscar.org. [cited 29 January 2017]. Available from: http://www.regiscar.org/Diseases_HSS_DRESS.html
 16. Tas Simonart T. Management of Drug Rash with Eosinophilia and Systemic Symptoms (DRESS Syndrome): An Update. *Dermatology*. 2003;206(4):353-356.
 17. Camus P, Foucher P. Pneumotox » Drug [Internet]. Pneumotox.com. 1997 [cited 29 January 2017]. Available from: <http://www.pneumotox.com/>
 18. MedWatch: The FDA Safety Information and Adverse Event Reporting Program [Internet]. Fda.gov. [cited 29 January 2017]. Available from: <http://www.fda.gov/Safety/MedWatch/default.htm>

FIGURE/VIDEO CAPTIONS *figures should NOT be embedded in this document*

Figure 1:

A: Plain chest radiograph of the patient on admission (I), after levetiracetam cessation and 12 days of prednisolone (II) and after levetiracetam cessation and 4 weeks of prednisolone (III).

B: Selected computed-tomography slices (performed on initial diagnosis) showing patchy areas of ground-glass throughout the lung fields.

C: Table showing eosinophil count before and throughout treatment.

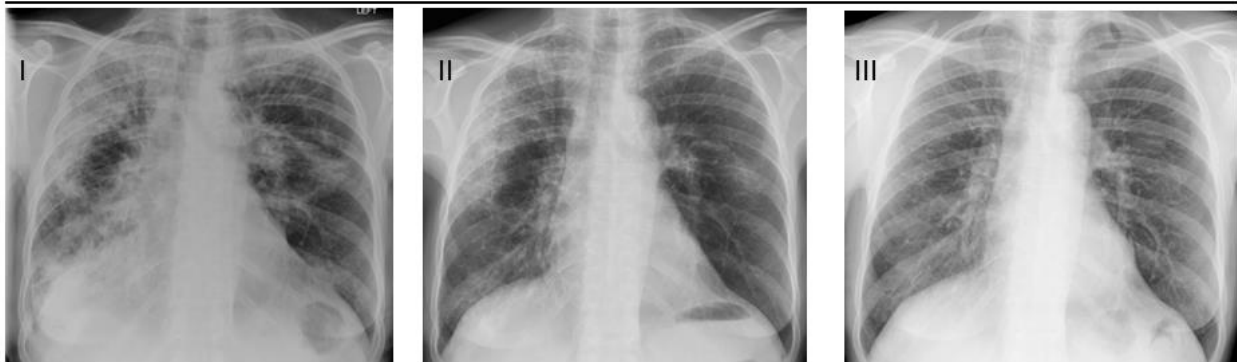Figure 2:

BMJ Case Reports

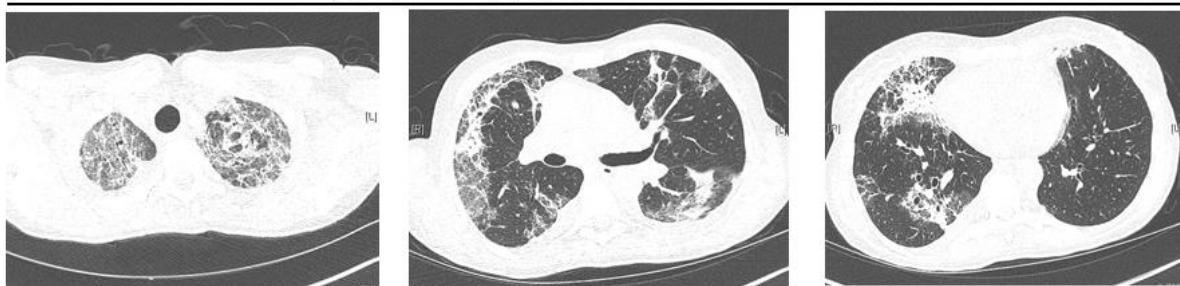Chemical structure of levetiracetam, phenytoin, carbamazepine and oxcarbazepine.
PATIENT'S PERSPECTIVE <i>Optional but strongly encouraged – this has to be written by the patient or next of kin</i>
Copyright Statement <p>I, <i>Aisling Fagan</i>, The Corresponding Author, has the right to assign on behalf of all authors and does assign on behalf of all authors, a full assignment of all intellectual property rights for all content within the submitted case report (other than as agreed with the BMJ Publishing Group Ltd) ("BMJ") in any media known now or created in the future, and permits this case report (if accepted) to be published on BMJ Case Reports and to be fully exploited within the remit of the assignment as set out in the assignment which has been read. http://casereports.bmj.com/site/misc/copyright.pdf.</p> <p>Date: 28th January 2017</p> <hr/>
PLEASE SAVE YOUR TEMPLATE WITH THE FOLLOWING FORMAT: Corresponding author's last name and date of submission, eg, Smith_September_2014.doc

BMJ Case Reports

(A) Chest radiographs: admission (I), twelve days (II) and four weeks (III) post-presentation



(B) Computed tomography at presentation: selected transverse images

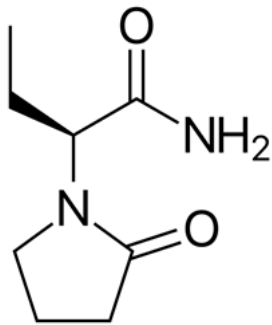


(C) Longitudinal charting of the peripheral eosinophil count

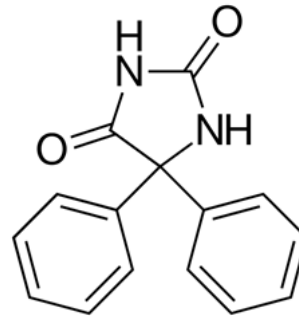
Timepoint	Baseline	At presentation	After 12 days of prednisolone and levetiracetam cessation	After 4 weeks of prednisolone and levetiracetam cessation
Eosinophil count ($\times 10^9/L$)	0.39	8.38	1.28	0.11

BMJ Case Reports

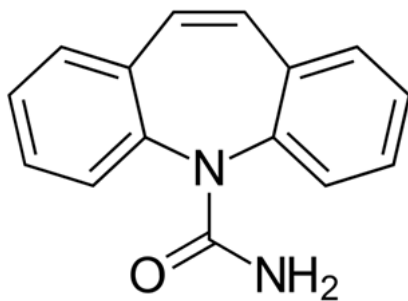
Levetiracetam



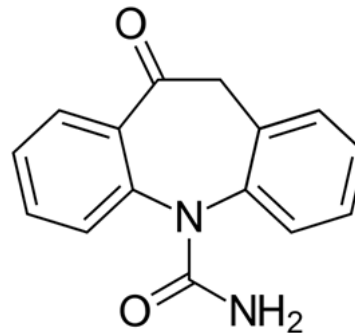
Phenytoin



Carbamazepine



Oxcarbazepine



All courtesy of Harbin, via Wikimedia Commons