



A missed scalp laceration causing avoidable sequelae

Shadi Basyuni^{a,b,*}, Andreana Panayi^{a,b}, Valmiki Sharma^a, Vijay Santhanam^a

^a Addenbrooke's Hospital, Cambridge, United Kingdom

^b University of Cambridge, United Kingdom

ARTICLE INFO

Article history:

Received 26 January 2016

Accepted 7 April 2016

Available online 11 April 2016

Keywords:

Laceration

Maxillofacial

Reconstructive

Wound healing

Infection

Secondary survey

ABSTRACT

INTRODUCTION: We present the case of an overlooked scalp laceration in an 81-year-old lady who presented with polytrauma following a fall down stairs. Complications that developed required more extensive treatment compared to what would have sufficed with early identification.

PRESENTATION OF CASE: Imaging on admission to hospital showed multiple vertebrae and rib fractures as well as a large cranial subcutaneous haematoma with no intracerebral bleed. Before the laceration was identified, the patient developed acute anaemia requiring transfusion. Continued reduction in haemoglobin levels called for a more thorough examination of the scalp. Investigation, following copious irrigation, revealed a large laceration. The presence of infection and necrotic tissue necessitated a general anaesthetic for debridement and closure.

DISCUSSION: Diagnostic errors are more common in patients presenting with multiple or severe injuries. Initial management in trauma cases should focus on more evident or life threatening injuries. However, it is important that reflections and recommendations are continually made to reduce diagnostic errors which are higher in polytraumatised patients.

Various factors including haemodynamic instability and patient positioning added to the elusive nature of this wound. Adequate examination of lacerations requires thorough cleaning as coagulated blood and other material may obscure findings. This is particularly important in scalp lacerations where the overlying hair can form a barrier that is effective at hiding the wound edges.

CONCLUSION: This case highlights the importance of a thorough secondary survey; an effective examination technique would have avoided the need for extensive treatment to manage the sequelae of the missed scalp laceration.

© 2016 The Authors. Published by Elsevier Ltd. on behalf of IJS Publishing Group Ltd. This is an open access article under the CC BY-NC-ND license (<http://creativecommons.org/licenses/by-nc-nd/4.0/>).

1. Introduction

Scalp lacerations are extremely common head injuries, yet they are often missed in polytraumatised patients. These patients can present in various medical states (such as cardiogenic shock) that can minimise bleeding from the scalp due to low perfusion pressures. The injury may also be overlooked as a clinician's attention is, understandably, focused on more evident or life threatening injuries.

Once the patient is stabilised and their blood pressure is re-established, the lesions can begin to bleed. Overlooked scalp lacerations can, consequently, result in significant blood loss leading to acute anaemia and potentially hypovolaemic shock. In addition, delayed treatment of scalp lacerations increases the possibility of contamination that could cause a significant infection. These infections, along with the resultant tissue changes, may necessitate

more extensive debridement before closure of the wound can be achieved. General anaesthesia is usually required in such cases.

These sequelae, along with the more invasive and complicated treatments required, can lead to increased morbidity and poorer outcomes. Moreover, discharge from hospital can be delayed causing further inconvenience for patients as well as the obvious economic implications.

2. Presentation of case

An 81-year-old woman presented with numerous injuries following a fall down a flight of stairs. Paramedics who accompanied her to the emergency department noted 500 mls of blood loss from a scalp wound which required bandaging.

On assessment, in the emergency department, the patient scored 15 on the Glasgow coma scale (GCS) but it was noted that she appeared pale. She reported retrograde amnesia as well as feeling dizzy. She had no recollection for her reasoning to go up the stairs. On removal of the head bandage, there was no bleeding from the scalp which had the appearance of a haematoma.

* Corresponding author at: Clinic 8, Addenbrooke's Hospital, Hills Road, Cambridge CB2 0QQ, United Kingdom.

E-mail address: shadi.basyuni@nhs.net (S. Basyuni).

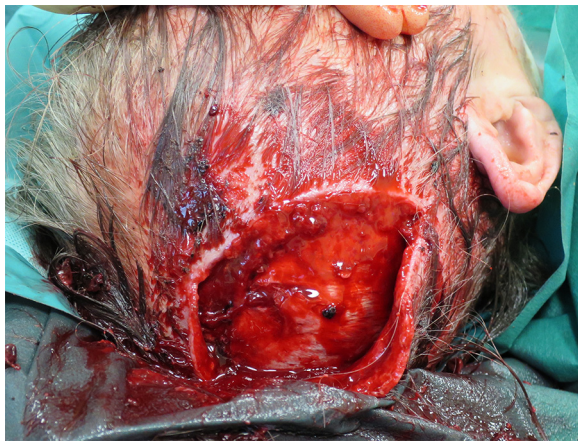

Fig. 1. Extent of scalp laceration evident following irrigation.

Computed tomography (CT) of the chest and abdomen showed multiple rib and vertebrae fractures. Cranial CT revealed a posterior soft tissue injury with no skeletal or intracranial involvement.

The patient's medical history was remarkable for mild vascular dementia, asthma, angina, hypothyroidism and congestive heart failure. She lives with her daughter and sleeps in a bedroom situated on the ground floor due to mobility issues. She is a non-smoker and does not consume alcohol.

3. Investigations

Blood tests on admission showed a raised white cell count ($16.03 \times 10^9/L$) and neutrophils ($14.17 \times 10^9/L$). Urinalysis was positive for nitrites and cultures grew *Escherichia coli* species. Initially, the haemoglobin level recorded was 99 g/L. Initial CT imaging taken in the primary survey showed multiple undisplaced rib fractures on the right side, a displaced fracture of the T8 vertebra and a fracture of the left lateral process of the L3 vertebra. Cranial CT showed significant soft tissue injury with a large subcutaneous haematoma posteriorly over the parietal bones. It was negative for any intracranial anomalies.

Due to the patient's T8 fracture, it was decided that a log roll was contraindicated, thus limiting the clinical examination. Further

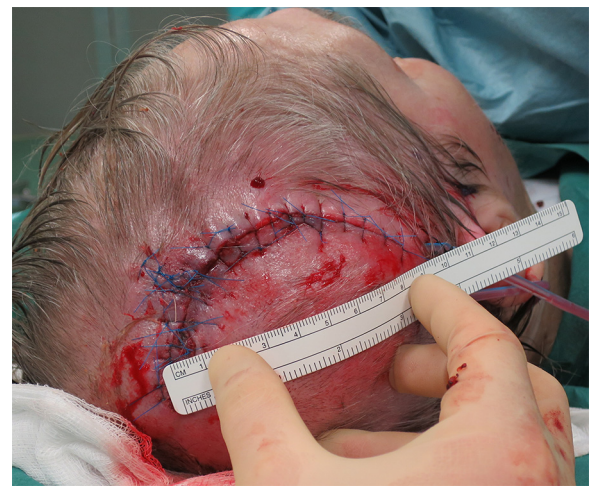

Fig. 2. Laceration following primary closure. Note the friable edges, particularly posteriorly.

plain film radiographs were carried out, as part of the secondary survey, which revealed no further injuries.

The patient required a blood transfusion after haemoglobin levels gradually deteriorated to 75 g/L. The undetermined cause of the normocytic anaemia called for further investigations. A thorough clinical examination of the scalp wound revealed that there was a laceration in addition to the haematoma. This was a large lesion spanning from the occipital protuberance across to the parietal bone and its depth was extending to the sub-galeal layer (Fig. 1). Retraction of the wound flap revealed a liquefying haematoma with signs of infection; there was frank discharge of pus and the area contained necrotic fat.

4. Differential diagnosis

This patient had a complex medical history with multiple factors that could have contributed to the fall. The increased neutrophils and presence of a urinary tract infection (UTI) may have contributed towards an altered mental state that caused her to uncharacteristically venture up the stairs unaccompanied. Failure to identify any

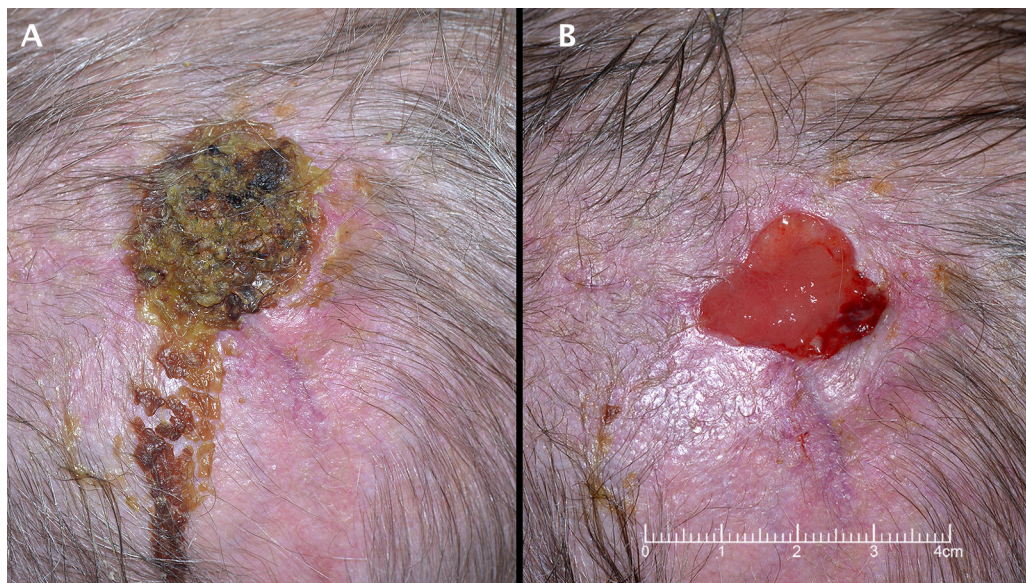


Fig. 3. Lesion on first review. (A) Before cleaning (B) after cleaning, to reveal granulating tissue.

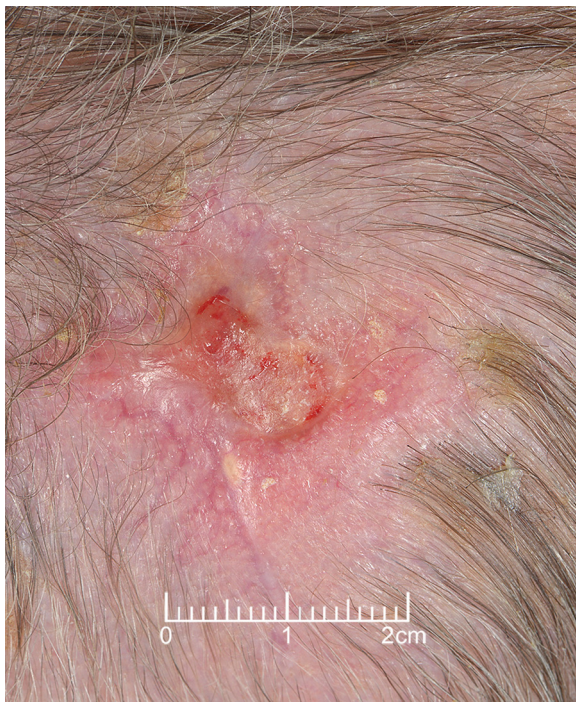

Fig. 4. Lesion on last review, following application of topical corticosteroid cream.

other cause of medical collapse indicates that the fall, itself, was most probably a mechanical fall due to the patient's pre-existing reduced mobility.

As previously discussed, the scalp lesion was initially misdiagnosed and managed as an isolated haematoma. However, following thorough clinical examination the laceration became evident. Several challenges existed that delayed the establishment of this correct diagnosis.

On initial presentation, there was no mention of active bleeding from the wound. This could have been due to reduced perfusion levels or clot formation occurring prior to admission. Following primary survey, the contraindication of the log roll meant that the wound was hidden as the patient was effectively immobile and bed-ridden. The patient's long hair also contributed to the occult nature of the laceration. A few days had passed before she regained mobility. By this stage the wound had formed a hard clot and transient bleeding was attributed to the patient scratching the area in a confused state.

Correct diagnosis was only achieved following thorough cleaning, which necessitated the use of local anaesthetic.

5. Treatment

All rib and vertebral fractures were managed conservatively, with minimal pain being reported by the patient. The bacterial species grown in the urine sample was sensitive to co-amoxiclav, which was administered intravenously.

Multidisciplinary team discussions, involving input from the patient's daughter, advised referral to a rehabilitation service to prevent further falls as well as the need for input from the social care team.

The scalp infection that had developed before identification of the laceration meant that a general anaesthetic was required for wound closure. Examination under anaesthetic also revealed that some of the wound edges were friable. The lesion was extensively debrided and necrotic tissue was removed before closure was achieved primarily (Fig. 2).

Post-operatively, the patient was continued on intravenous antibiotics. On the ward her condition stabilised and a social care plan was organised. She was discharged eleven days after the surgery, following the removal of sutures, with no signs of further infection or complications.

6. Outcome and follow-up

The patient was reviewed two months post-surgery complaining of an area of crusting and weeping. On examination the majority of the wound had healed uneventfully. Cleaning of the crusting lesion revealed a granulating area measuring roughly three centimetres in diameter (Fig. 3). Following a course of topical corticosteroid application, this lesion continued to heal well and the patient had no complaints (Fig. 4).

7. Discussion

Diagnostic errors are more common in patients presenting with multiple or severe injuries. Management protocols in acute trauma correctly, focus on more evident or life threatening injuries during the initial stabilisation phases. However, it has been shown that these patients, who often require resuscitation or urgent treatment have a higher rate of diagnostic error [1]. Poor radiological analysis, haemodynamic instability and inadequate assessment are some proposed factors that could contribute to these errors [2].

The lack of active bleeding from the scalp wound added to its elusive nature. The blood loss reported before the patient arrived to the hospital may have been enough to reduce perfusion to the scalp thus minimising bleeding. This phenomenon has been reported previously where it was noted that the wound may restart bleeding following haemodynamic stabilisation [3]. Early management is advised, especially as undiagnosed scalp lacerations can cause significant blood loss leading to acute anaemia, as was probably the case in this patient, and even haemorrhagic shock [4].

It is obviously important that reflections and recommendations are continually made to reduce diagnostic errors. The contraindication of logrolling in this case precluded an important part of the secondary survey. This, along with a poor history from the patient were significant factors in delaying the identification of the laceration. To overcome this, suggestions have been made that patients are re-examined 1–3 days post admission, when the patient's mental status improves, or even the implementation of a tertiary survey [5,6].

Adequate examination of lacerations requires thorough cleaning as coagulated blood and other material may obscure findings [7]. This is particularly important in scalp lacerations where the overlying hair can form a barrier that is effective at hiding the wound edges. Blood supply to a wound flap can be compromised if edges are not opposed early. This can lead to wound breakdown and unfavourable results.

8. Conclusion

Extensive efforts should be placed on preventing a missed diagnosis. In the case of overlooked scalp lacerations, they are frequently associated with extended morbidity and hospital admission that are easily avoidable.

Conflict of interest

Nil conflict of interest.

Sources of funding

No funding was requested for this case report.

Ethical approval

Ethics committee approval not needed for this case report.

Consent

“Written informed consent was obtained from the patient for publication of this case report and accompanying images. A copy of the written consent is available for review by the Editor-in-Chief of this journal on request”.

Authors contribution

Vijay Santhanam and Valmiki Sharma conceived the idea of the project. Shadi Basyuni and Andreana Panayi carried out the literature search and wrote up the paper. All authors contributed to refinement of the case report and approved the final manuscript.

Guarantor

Shadi Basyuni.

References

- [1] [P.A. Frawley, Missed injuries in the multiply traumatised, *Awl. N. Z. J. Surg.* 63 \(12\) \(1993\) 935–939.](#)
- [2] [T.A. Hamdan, Missed injuries in casualties from the Iraqi-Iranian war: a study of 35 cases, *Injury* 18 \(1\) \(1987\) 15–17.](#)
- [3] [B. Turnage, K.I. Maull, Scalp laceration: an obvious 'occult' cause of shock, *South. Med. J.* 93 \(3\) \(2000\) 265–266.](#)
- [4] [M.J. Lemos, D.E. Clark, Scalp lacerations resulting in haemorrhagic shock: case reports and recommended management, *J. Emerg. Med.* 6 \(5\) \(1988\) 377–379.](#)
- [5] [W.G. Ward, J.A. Nunley, Occult orthopaedic trauma in the multiply injured patient, *J. Orthop. Trauma* 5 \(3\) \(1991\) 308–312.](#)
- [6] [B.L. Enderson, D.B. Reath, J. Meadors, et al., The tertiary trauma survey: a prospective study of missed injury, *J. Trauma* 30 \(6\) \(1990\) 666–670.](#)
- [7] [S.J. Goodman, L. Cahan, A.W. Chow, Subgaleal abscess: a preventable complication of scalp trauma, *West. J. Med.* 127 \(2\) \(1977\) 169–172.](#)

Open Access

This article is published Open Access at sciedirect.com. It is distributed under the [IJSCR Supplemental terms and conditions](#), which permits unrestricted non commercial use, distribution, and reproduction in any medium, provided the original authors and source are credited.