

European Journal of Orthopaedic Surgery & Traumatology

Ankle Fusion with Tibiotalocalcaneal Retrograde Nail for Fragility Ankle Fractures: Outcomes at a Major Trauma Centre

--Manuscript Draft--

Manuscript Number:	EJOS-D-21-00751R1
Full Title:	Ankle Fusion with Tibiotalocalcaneal Retrograde Nail for Fragility Ankle Fractures: Outcomes at a Major Trauma Centre
Article Type:	Original Article
Corresponding Author:	Victor Lu University of Cambridge School of Clinical Medicine UNITED KINGDOM
Corresponding Author Secondary Information:	
Corresponding Author's Institution:	University of Cambridge School of Clinical Medicine
Corresponding Author's Secondary Institution:	
First Author:	Victor Lu
First Author Secondary Information:	
Order of Authors:	Victor Lu
	Maria Tennyson
	James Zhang
	Azeem Thahir
	Andrew Zhou
	Matija Krkovic
Order of Authors Secondary Information:	
Funding Information:	
Abstract:	<p>Purpose Fragility ankles fractures in the geriatric population are challenging to manage, due to fracture instability, soft tissue compromise, and patient co-morbidities. Traditional management options include open reduction internal fixation, or conservative treatment, both of which are fraught with high complication rates. We aimed to present functional outcomes of elderly patients with fragility ankle fractures treated with retrograde ankle fusion nails.</p> <p>Methods A retrospective observational study was performed on patients who underwent intramedullary nailing with a tibiotalocalcaneal nail. Twenty patients met the inclusion criteria of being over sixty and having multiple co-morbidities. Patient demographics, AO/OTA fracture classification, intra-operative and post-operative complications, time to mobilisation and union, AOFAS and Olerud-Molander scores, and patient mobility were recorded.</p> <p>Results There were 7 males and 13 females, with a mean age of 77.82 years old, five of whom are type 2 diabetics. Thirteen patients returned to their pre-operative mobility state, and the average Charlson Comorbidity Index (CCI) was 5.05. Patients with a low CCI are more likely to return to pre-operative mobility status ($p=0.16$; $OR=4.00$). All patients achieved radiographical union, taking on average between 92.5 days to 144.6 days. The mean post-operative AOFAS and Olerud-Molander scores were 53.0 and 50.9, respectively. There were four cases of superficial infection, four cases of broken or loose distal locking screws. There were no deep infections, periprosthetic fractures, nail breakages, or non-unions.</p> <p>Conclusion</p>

	Tibiototalcalcaneal nailing is an effective and safe option for managing unstable ankle fractures in the elderly. This technique leads to lower complication rates and earlier mobilisation than traditional fixation methods.
--	--



**UNIVERSITY OF
CAMBRIDGE**

Division of Trauma and
Orthopaedic Surgery

**Box 180
Addenbrooke's Hospital,
Hills Road,
Cambridge
CB2 0QQ**

Tel +44 (1)223 217551
Fax +44 (1)223 214094
pa@orthopaedics.cam.ac.uk

November 2nd 2021

Professor Cyril Mauffrey
Editor-in-chief
European Journal of Orthopaedic Surgery & Traumatology

Dear Prof. Mauffrey,

**Re: Ankle Fusion with Tibiototalcaneal Retrograde Nail for Fragility Ankle Fractures:
Outcomes at a Major Trauma Centre**

Thank you very much for reviewing our submission and providing us with the reviewers' comments. We have revised our manuscript taking into account the reviewers' comments and highlight the responses to the comments below.

Reviewer 1 Comments	Authors' Responses
Inclusion criteria need to be more strict and more defined. What was the criteria of fragility fractures , why the open fractures were included, why the pilot fractures were included?	We have clarified and made the inclusion criteria more well-defined. We have also included a definition of fragility fractures in the introduction section on page 2. Open fractures were included because all nine were caused by low-velocity trauma which is within the scope of our definition of a fragility fracture.
I could find at least 2 RCT comparing ORIF and TCC nailing in the fragility fractures: Tibiototalcaneal Intramedullary Nailing for Unstable Geriatric Ankle Fractures 2021 (Kulakli-Inceleme et al.) The role of intramedullary fixation in ankle fractures - A systematic review (Jordan et al.) Fragility fractures of the ankle in the elderly: Open reduction and internal fixation versus tibio-talo-calcaneal nailing: Short-term results of a prospective randomized-controlled study. (Georgiannos et al.)	Thank you very much for suggesting these three studies. The paper by Kulakli-Inceleme et al. is reference number 20 in the manuscript, and is located in three different sections. The paper by Jordan et al. is reference number 17 in the manuscript, and is located in three different sections. The paper by Georgiannos et al. is reference number 3 in the manuscript, and is located in three different sections.
1-The authors did not define what is a fragility ankle fracture	We have now defined a fragility ankle fracture in the introduction as one that occurs in patients

	over 60, as a result of minimal trauma, and in patients with osteoporotic bone.
2-Almost 50% of the patients had open ankle fractures (was it low energy , what was the mechanism of injury in the open fracture patient, did that affect the outcome?)	All nine open fracture patients in our cohort acquired low-velocity trauma, with six suffering a fall from standing height, and three tripping over on stairs; these injury mechanisms were the same as those that caused the eleven closed fractures in our cohort.
3- Almost 40% of the cohort were non primary cases (failed conservative , failed ORIF and failed TCC)	<p>Tibiototalcaneal nailing was used as a salvage procedure for patients who couldn't be adequately managed by conventional methods.</p> <p>Our aim was to present clinical and functional outcomes of elderly patients with fragility ankle fractures treated with retrograde TTC nails, and hence included patients who received TTC nailing as a primary treatment, as well as patients who received TTC nailing as a 'salvage procedure'</p>
4- In 3 cases no joint preparation was done compared to the other 18. why was the decision not to prepare the joints in these cases ?	The surgeons who elected to not prepare the joints felt that doing so would devascularise the talar fragments excessively, increase surgical insult and create an unnecessarily invasive procedure that would introduce wound healing issues, in return for arthrodesis union which is hard to achieve in a host with multiple co-morbidities.

Reviewer 3 Comments	Authors' Responses
Comment 1: In the abstract: it would be appropriate to refer to the characteristics of the study.	We have included the statement in the abstract that this a retrospective observational study.
Comment 2: In the introduction: Some information about etiology, diagnosis and treatment of Fragility ankle fractures should be deepened please adding appropriate bibliographical references. (Roux S, et al (2018) "Risk of Subsequent Fragility Fractures Observed After Low-Trauma Ankle Fractures").	<p>Thank you very much for the suggesting this study.</p> <p>The paper by Roux et al. is reference number 13 in the manuscript.</p> <p>We have added a paragraph to the introduction using the study by Roux et al. as a guide, whilst also including other relevant literature to address the aetiology, diagnosis, and treatment of fragility ankle fractures adequately and succinctly.</p>
Comment 3: In the introduction: "These fractures are difficult to manage not least because of osteoporosis, whose incidence is also on the rise due to increasing life expectancy, together with other systemic disorders such as diabetes." Please adding appropriate bibliographical references.	Appropriate references have been added, as well as some relevant literature discussing the relationship between fragility fractures and osteoporosis.
Comment 4: In the materials and method: please clearly indicate the exclusion criteria in this study.	We have clarified and made the exclusion criteria more well-defined.
Comment 5: In the materials and method: Were all surgical procedures performed by the same orthopedic surgeon?	Yes, all ankle fusion procedures were performed by one surgeon M.K.
Comment 6: In the materials and method: "All patients had multiple co-morbidities, which was quantified using the Charlson co-morbidity index (CCI); average score was 5.05." Please adding appropriate bibliographical references about Charlson co-morbidity index.	The appropriate reference have been added, which is Charlson's original paper on CCI.
Comment 7: In the Results: How long did it take to re-evaluate the patients clinically and radiographically?	<p>We apologise for not understanding the question, but here is how we interpreted it:</p> <p>Patients were re-evaluated clinically and radiography on average 30 days after discharge, followed by clinics at 4 week intervals.</p>
Comment 8: In the Results: Were the hospitalization times the same in all patients?	Hospitalisation times were different for patients, but the average length of hospital stay was 10.8 days (range 2-31).

Comment 9: In the discussion: It would be appropriate to refer to previous studies carried out on the same topic, for example: (Testa G, et al (2019) "Negative prognostic factors in surgical treatment for trimalleolar fractures").	<p>Thank you very much for the suggesting this study.</p> <p>The paper by Testa et al. is reference number 31 in the manuscript, and is located in two different sections.</p>
--	--

We are grateful to the reviewers for their comments. We believe that the comments have helped improve the manuscript considerably, and we are very grateful for their input.

Yours Sincerely,



Matija Krkovic PhD

Consultant Orthopaedic Trauma Surgeon, Addenbrookes Hospital, Cambridge

Tel: +44 (0) 7768 510601; E-mail: matija.krkovic@addenbrookes.nhs.uk

1 Ankle Fusion with Tibiotalocalcaneal Retrograde Nail for Fragility 2 Ankle Fractures: Outcomes at a Major Trauma Centre

4 Abstract

5 **Purpose**

6 Fragility ankles fractures in the geriatric population are challenging to manage, due to fracture
7 instability, soft tissue compromise, and patient co-morbidities. Traditional management options
8 include open reduction internal fixation, or conservative treatment, both of which are fraught
9 with high complication rates. We aimed to present functional outcomes of elderly patients with
10 fragility ankle fractures treated with retrograde ankle fusion nails.

11 **Methods**

12 A retrospective observational study was performed on patients who underwent intramedullary
13 nailing with a tibiotalocalcaneal nail. Twenty patients met the inclusion criteria of being over
14 sixty and having multiple co-morbidities. Patient demographics, AO/OTA fracture classification,
15 intra-operative and post-operative complications, time to mobilisation and union, AOFAS and
16 Olerud-Molander scores, and patient mobility were recorded.

17 **Results**

18 There were seven males and thirteen females, with a mean age of 77.82 years old, five of whom
19 are type 2 diabetics. Thirteen patients returned to their pre-operative mobility state, and the
20 average Charlson Comorbidity Index (CCI) was 5.05. Patients with a low CCI are more likely to
21 return to pre-operative mobility status ($p=0.16$; $OR=4.00$). All patients achieved radiographical
22 union, taking on average between 92.5 days to 144.6 days. The mean post-operative AOFAS and
23 Olerud-Molander scores were 53.0 and 50.9, respectively. There were four cases of superficial
24 infection, four cases of broken or loose distal locking screws. There were no deep infections,
25 periprosthetic fractures, nail breakages, or non-unions.

26 **Conclusion**

27 Tibiotalocalcaneal nailing is an effective and safe option for managing unstable ankle fractures
28 in the elderly. This technique leads to lower complication rates and earlier mobilisation than
29 traditional fixation methods.

31 **Keywords:** Ankle fusion, Tibiotalocalcaneal nailing, Ankle fractures, Mobility, Co-morbidity

Introduction

Fragility ankle fractures are increasing in incidence, and is now the third most common type of fracture in the elderly, after hip and distal radius fractures, with 184 cases per 100,000 people per year [1]. The rising life expectancy contributes to the growing number of cases, which has been projected to increase 25% by 2050 [1,2]. Ankle fractures show a bimodal age distribution, with the majority in men seen between the ages of 15 and 24, whilst the highest incidence in females is between 75 and 84 years old [2]. These fractures are difficult to manage not least because of osteoporosis, whose incidence is also on the rise due to increasing life expectancy, as well as other co-morbidities such as diabetes [3,4]. Osteoporosis is responsible for over 9 million fractures a year, and creates fractures patterns that are more complex and unstable [5]. Despite a Korean study suggesting that body mass index (BMI) rather than bone mineral density (BMD) is a risk factor for ankle fracture, which could be due to the small sample size and retrospective nature of the study [6], a meta-analysis of over 25000 patients demonstrated a significant association between fragility ankle fractures in the elderly population and reduction in BMD [7].

A fragility ankle fracture was defined as one that occurs in patients over 60, as a result of minimal trauma, and in patients with osteoporotic bone [8,9]. A meta-analysis with over 60000 patients concluded that a previous fragility fracture (FF) located anywhere increases the risk of acquiring a subsequent fragility fracture (RR=1.86; 95% CI=1.75–1.98) which is largely independent of BMD [10]. Nevertheless, some studies suggest that ankle FFs have a lower predictive value for subsequent FFs than FFs occurring at more typical osteoporotic locations such as the hip and vertebrae [11]. This could be because ankle fractures have a weaker dependence on age and bone mass [12], are more driven by mechanical factors such as twisting or distortion rather than osteoporosis [13], and have a stronger relationship with lifestyle factors [14]. Risk factors also differ from FFs at other sites, for example menopause was strongly and linearly related to wrist fractures but not to ankle fractures [15]. Multivariate analyses of a cohort of patients aged ≥ 50 concluded that those with ankle FFs who are still physically active or at low/moderate risk according to the WHO's fracture risk assessment tool (FRAX) may not need subsequent investigation or treatment [13].

The goal for ankle fracture primary management includes anatomical restoration of the tibiotalar mortise, a stable and pain-free ankle, and a rapid return to baseline mobility. Particularly in the elderly, important considerations are early mobilisation and weight bearing, the benefits of which have been shown in a study investigating mortality and immobility in hip fracture patients [16]. Prolonged periods of non-weight bearing is difficult for the elderly, may lead to complications such as pressure ulcers and deep vein thrombosis, and often leads to a lengthy stay at a nursing home. Management of fragility ankle fractures in the elderly is difficult, because of poor bone quality, healing ability, soft tissue condition, suboptimal skin quality, and lack of patient compliance. Intramedullary nails are beneficial since they allow early weight bearing, require only a small incision, and minimises soft tissue trauma [17]. Since 2005, the literature contains optimistic reports of using tibiototalcalcaneal (TTC) nails for treatment, with no non-union [18] and immediate weight-bearing post-operatively [19]. However, few studies assessed functional outcomes with adequate follow-up times [18-22].

This paper presents a cohort of fragility ankle fractures in the elderly, treated with retrograde ankle fusion nails. The primary objective was to assess whether the number of co-morbidities is associated with a return to pre-operative mobility status and post-operative complications. The secondary objective was to assess the time to radiographical union and patient reported outcome measures (PROMs).

Methodology

The patient record database was retrospectively reviewed for patients who received a retrograde ankle fusion nail. Our inclusion criteria were:

- Age over 60.
- Patients who are able to give informed consent.
- Patients with two or more co-morbidities.
- Patients who are unable to comply with post-operative non-weight bearing instructions due to mental or physical reasons.
- Patients with poor bone stock, verified by radiological evidence of osteopenia or a history of fragility fractures.
- Unstable fracture pattern necessitating operative management, as determined by a medial clear space ≥ 5 mm on anteroposterior radiographs taken in dorsiflexion.
- Poor soft tissue condition around the ankle upon physical examination

In addition to excluding patients who didn't meet the aforementioned criteria, the following patients were also excluded:

- Patients who were not fit for anaesthesia
- Patients with high energy mechanism of injury
- Patients with peripheral vascular disease
- Patients with previous fracture of the affected limb
- Pathological fractures

Out of 171 patients who received a hindfoot nail, twenty patients met the inclusion criteria. Thirteen were female and seven were male. The mean age was 77.8 years old (range 61 to 95). Injury was low energy in all patients, including the nine patients who had open fractures, two of whom had Gustilo-Anderson type 3a fractures and one with Gustilo-Anderson type 3b fracture, all of whom required soft tissue coverage. Fractures were classified using the Arbeitsgemeinschaft für Osteosynthesefragen/Orthopaedic Trauma Association (AO/OTA) classification. There were 7 trimalleolar fractures (three AO/OTA 44C1, three 44B2, one 44B1), 12 bimalleolar fractures (six AO/OTA 44C1, four 44A2, two 44B2), and one pilon fracture (AO/OTA 43C1). Twelve operations were performed as primary fracture management, four for failed conservative treatment, three for failed open reduction internal fixation (ORIF), and one for failed TTC nailing at a different hospital. All ankle fusion procedures were performed by one consultant orthopaedic surgeon (MK). The average follow-up time was 499.3 days.

All patients had multiple co-morbidities, which was quantified using the Charlson co-morbidity index (CCI) [23]; average score was 5.05. CCI produces a comorbidity-age combined risk score, and can be converted using a formula to give a predicted 10-year survival percentage, based on the 10-year survival from a theoretical low-risk population (98.3%).

$$\text{Predicted 10-year survival} = 0.983^{(e^{0.9 \times \text{CCI}})}$$

As CCI increases from 0 to 6, predicted 10-year survival percentage drops as follows: 99,96,90,77,53,21. We defined a high CCI as a value that has a corresponding 10-year survival of less than 50%, i.e. $\text{CCI} \geq 5$; the remainder ($\text{CCI} < 5$) is defined as low CCI.

The decision to proceed with TTC nailing was made by the consultant, following assessment of patient's preoperative mobility, co-morbidities, bone quality, fracture pattern/stability, and ability to comply with non-weight bearing status. On admission, patients were managed with our standard trauma protocol. All open fracture patients received prophylactic antibiotics, as per BOAST guidelines for open fracture management [24]. A standard ankle fusion procedure was followed. Three operations were performed by senior fellows, the rest (85%) were consultant-led. Patients on average spent 10.8 days in hospital. One patient spent 31 days due to a heel ulcer which got infected, leading to osteomyelitis of the calcaneum. This was successfully treated with teicoplanin and ciprofloxacin. PROMs were collected twelve months after surgery, namely AOFAS ankle-hindfoot score and Olerud and Molander (O&M) score. PROMs were unable to be collected in three patients who passed away within one month of surgery.

Statistical analysis was performed using IBM SPSS Statistics version 27. Categorical binary data was analysed with Pearson's Chi-squared test. A significance value of $p \leq 0.05$ was used.

This study was registered with the clinical research department on May 25th 2021; registration number PRN9832.

Results

Demographical information is provided in table 1 and clinical outcomes in table 2. Thirteen patients (65%) returned to their pre-operative mobility state and seven patients had inferior post-operative mobility compared to pre-operative mobility. Five patients who could previously walk independently subsequently required a crutch at all times. Two patients who previously used a walking frame subsequently required a wheelchair. Compared to those with a high CCI score ($\text{CCI} \geq 5$), patients with a low CCI score ($\text{CCI} < 5$) were more likely to return to their pre-operative mobility status ($p=0.16$; $\text{OR}=4.00$).

After 24 hours of strict elevation of the affected limb, all patients were allowed to fully mobilise, as far as pain could be tolerated. The average time to mobilisation was 7.63 days. Those who could not mobilise after day 4 all suffered from complications. One patient who could only mobilise after 24 days had a hindfoot ulcer, grade 3 pressure ulcers, and severe back pain due to non-union of a previous public rami fracture.

The average length of hospital stay was 10.8 days (range 2-31). Patients were re-evaluated clinically and radiography on average 30 days after discharge, followed by clinics at 4 week intervals. All patients eventually achieved radiographic union, defined as the presence of bony bridging on antero-posterior and lateral X-ray views, together with painless full weight bearing. Bone union took on average between 92.5 days and 144.6 days to occur. Average AOFAS score 6 months post-injury was 53.0 (17-88). The O&M score was not calculated pre-injury, but the average value 6 months post-injury was 50.9 (range 20-85).

The six-month mortality rate was 15% (3/20). One patient passed away eleven days after surgery, due to post-operative ileus, causing vomiting and aspiration pneumonia, eventually leading to respiratory failure. Surgical complications included four superficial infections (20%), treated with topical antibiotics. Patients with a high CCI were more likely to acquire superficial infections ($p=0.264$, $OR=3.857$). Four patients experienced pain due to broken or loose distal locking screws, which were subsequently removed. Otherwise, metalwork removal was not performed. One patient experienced paraesthesia in the distribution of superficial peroneal nerve and sural nerve, probably damaged iatrogenically, or due to scarring of soft tissue. There were no deep infections, periprosthetic fractures, nail breakages, or non-unions. However, one patient had delayed union (279 days to union), which eventually united after regular observation, and lymphoedema causing an equinus deformity, leading to a low AOFAS score of seventeen.

Discussion

Patient Demographics and Surgical Management

Surgical management of fragility fractures in the elderly is challenging, with traditional management yielding poor results [25]. Conservative management using fracture manipulation or plaster mobilisation produced a non-union rate of 73% [26], with 79% experiencing chronic pain [27]. ORIF produces poor outcomes in the elderly due to patient-specific conditions such as poor condition of the skin and soft tissue, which is exacerbated by the fracture, poor bone quality, limited pre-injury mobility, advanced age, complex and unstable fracture patterns [28]. Surgical wound complications are a concern, as well as an increased risk of deep infection and delayed wound healing due to conditions such as diabetes and peripheral vascular disease, and potential use of corticosteroids [29]. Studies that performed ORIF reported a 19% non-union rate and 43% (37/86) patient dissatisfaction rate [25]. Beauchamp et al. reported a 23% wound complication incidence, and anatomical fixation was achieved in only 54% (38/71); this was significantly more biased towards men (17/22 in men versus 21/49 in women), perhaps due to an increased proportion of osteoporotic bone in women during surgery, increasing the morbidity associated with ORIF [4]. Georgiannos et al. performed a randomised control study between patients treated with TTC nailing and ORIF; the former cohort had a reoperation rate of 2.7%, whilst the latter was 13.8% [3]. Ali et al. reported optimistic results using ORIF, with 8.7% (10/115) malunion rate and only 1 patient with non-union [30]. However, it is a biased study since they excluded those with severe mobility problems, who are most likely to fall and injure themselves, and likely to have osteoporotic bones. Litchfield et al. suggested that inactivity

mitigates against ORIF success, and those who were active on their feet pre-injury had the best results [25]. However, the majority of our cohort were dependent on a crutch or frame pre-injury, and all had some degree of impaired mobility.

The average age of our cohort at time of injury was 77.8, which is similar to other cohorts [18,21]. According to our definition for a fragility fracture, only those over 60 years old were included; this itself was suggested to be a negative prognostic factor for surgical treatment of trimalleolar ankle fractures according to O&M score ($p = 0.000002$) and VAS score ($p=0.048$) [31]. The average age of women and men in our cohort were 82.8 and 70.7, respectively; this was surprising given that women over 50 have a four-fold higher rate of osteoporosis than men [32]. The average hospital stay of 10.8 days was shorter than cohorts treated conservatively or by ORIF [27,28].

The proportion of open fractures in our cohort (45%) is higher than those in the literature [8,22], whilst some cohorts had no patients with open fractures [18,19]. This could be due to our clinic being located in a major trauma centre. Although commonly associated with high-energy injuries, all nine open fracture patients in our cohort acquired low-velocity trauma, with six suffering a fall from standing height, and three tripping over on stairs. The open fracture was likely caused by sharp fracture fragments piercing through the soft tissue and skin in patients with poor soft tissue condition. A large proportion of our cohort (40%) received TTC nailing as a 'salvage procedure' after unsuccessful prior management. Despite being higher than other cohorts [21], a fair comparison may not be possible, due to the lack of definitive guidelines for when TTC nailing should be used first-line, with surgeons themselves deciding if patients fit the criteria to receive TTC nailing. Nevertheless, this salvage technique has shown promising results in previous reports, with radiological union occurring three months following surgery [33].

Ankle and subtalar joints were prepared prior to nail insertion, meaning that they were denuded of cartilage down to subchondral bone (figure 1, figure 2). Surgeons in three operations elected to not prepare the joints (figure 3, figure 4). Studies mention that preparing the subtalar joint reduces non-union rate [20,34]; nevertheless, whether or not subtalar joint needs open debridement remains a contentious point. The surgeons who elected to not prepare the joints felt that doing so would devascularise the talar fragments excessively, increase surgical insult and create an unnecessarily invasive procedure that would introduce wound healing issues, in return for arthrodesis union which is hard to achieve in a host with multiple co-morbidities. Preparing the joint is not a common routine in the literature, and all three patients managed without joint preparation achieved radiographical union. Perhaps joint preparation is more important for young, active patients, whereby hardware failure is more likely due to cyclic loading on the metalwork.

Mobility

Ankle fusion is not necessarily a life changing procedure. Georgiannos et al. reported that 81.8% of patients treated with a hindfoot nail returned to their pre-operative mobility status [3]. The figure was 65% in our cohort. We found that having a low number of co-morbidities (low CCI

score) is positively correlated with regaining one's pre-operative mobility ($p=0.160$; $OR=4.00$). However, the association was not statistically significant, probably because our sample size was too small to be adequately powered. Additionally, we noticed that those who took longer than 4 days post-surgery to mobilise all suffered some form of post-operative complication. This is similar to Lemon et al. who found that all who failed to mobilise within 72 hours of surgery suffered a post-operative medical complication [19]. Furthermore, we found that patients with a high CCI score are likely to get superficial infections ($p=0.264$; $OR=3.857$). All this suggests that patients who have more co-morbidities (higher CCI score), who are less likely to return to pre-operative mobility status, are also expected to suffer from post-operative complications, likely superficial infections.

Diabetes Mellitus

Five patients (25%) in our cohort were type 2 diabetics, two of whom had superficial wound infection (40%). Management of patients with diabetes adds another layer of complexity, given the high infection rates and wound healing problems that are known to be associated [35]. In their cohort of 93 patients treated with ORIF, Low and Tan [36] reported five patients with wound infections, all of whom were type 2 diabetics. With a 50% infection rate in their diabetic cohort, this illustrates that infection is a serious problem in surgically treated diabetics with ankle fractures. Diabetics are also at increased risk of other complications such as non-union and post-traumatic arthritis; Blotter et al. suggested a 2.76-fold higher relative risk for postoperative complications in patients with diabetes mellitus compared to control group [37]. This could be due to diabetic neuropathy, leading to unprotected weightbearing on the senseless foot. Furthermore, diabetes and obesity are closely interlinked, with four out of five diabetics (80%) in our cohort being obese ($BMI \geq 30$). This could be due to biochemical relationships between insulin signalling and adipose tissue, including inhibition of intracellular lipase and increased triacylglycerol synthesis in liver [38]. Not only is average BMI in ankle fracture patients higher than age-matched controls [6], but a retrospective study of 48 patients suggested that morbidly obese patients ($BMI \geq 40$) is a negative prognostic factor for ankle fracture management [31].

Complications

Our overall complication rate was 20% (4/20). This falls within the range of 18 to 22.6% for TTC nailing as quoted in a recent systematic review [17], which also reported that fibula nails have a lower complication rate of 0 to 22%. Nevertheless, our complication rate was lower than patient cohorts treated with ORIF [3,4]. Perhaps due to our high percentage of open fractures, superficial infection rate was higher than the range of 0-6.5% quoted in the literature [8,22]. We report no cases of deep infection or non-unions, which is very favourable compared to other management options such as ORIF [4,27], as well as other studies utilising TTC nailing [8,20,22], with non-union rates of 30% being reported [20]. We also report no periprosthetic fractures, even though a long nail was not used, which was suggested to prevent periprosthetic fractures [22]. Perhaps this was due to low functional demands in our cohort. Four patients

required removal of a broken or loose locking screw; one used a crutch whilst three did not need a walking aid. These patients may have been too 'active' to receive TTC nailing, however they were selected due to their poor skin and soft tissue conditions, and perceived lack of ability to comply with non-weight bearing instructions.

PROMs and Bone union

AOFAS scores was reported in only one other study [39]. Our average value of 53.0 is lower than their value of 85.4. Reason could be two-fold. We reported AOFAS scores at 6 months post-injury, but Al-Ashhab et al. reported it at final follow-up [39]. Also, 45% of our patients had open fractures, whereas their cohort had no open fractures [39]. Our average O&M score 6 months post-injury of 50.9 concurs with a recent systematic review on intramedullary nailing in ankle fractures, which suggested that the mean O&M score for patient cohorts treated with TTC nailing in the literature was 50-62 [17]. Nevertheless, the limitations of the systematic review, namely the differences in patients included, varying definitions of outcome scores, and the low quality of included studies precluded the ability to draw definitive conclusions [17].

Few studies report time to union. Bone union took on average 92.5 days to 144.6 days to occur, which was longer than the average time to union of 63 days reported by Jonas et al. [18]. However, this may not be a fair comparison since in retrospective studies, finding when exactly union occurred is difficult. Patients do not have frequent, evenly-spaced radiological follow-ups. Furthermore, COVID-19 has exacerbated this issue, with virtual follow-ups prolonging the gap between radiological checks. This is the reason we preferred to give a time interval within which bone union occurs, rather than a definitive number.

Limitations

Our study has a few limitations, not least being the retrospective study design. There was no control group to compare with other management options such as ORIF or conservative treatment. Our population size is relative small and heterogenous, with patients having various fracture patterns and classifications. Also, we could not obtain pre-operative O&M scores, which would have been useful to compare with post-operative scores. Our cohort included patients who received TTC nailing as a primary treatment, as well as patients who received TTC nailing as a 'salvage procedure' after failed treatment using more conventional methods. Our population size was not large enough to provide a comparison between these two groups. Furthermore, there is a lack of definitive guidelines for when TTC nailing should utilised as primary management for ankle fractures.

Conclusion

TTC nailing is an effective treatment methodology for the low-demand geriatric patient with unstable fragility ankle fractures, and should be added to the armamentarium of management

options for fragility ankle fractures in the elderly. It effectively stabilises the hindfoot and encourages early weight-bearing, maintaining mobility, which is important for preventing the loss of socioeconomic independence. TTC nailing limits soft tissue injury and has few complications, compared to other treatment options such as ORIF or conservative management. It is not a life-changing procedure, with many being able to return to their pre-operative mobility status, however, the number of co-morbidities is a negative predictive factor for returning to pre-operative mobility status, and a positive predictive factor for the development of post-operative complications.

Acknowledgements

No services of an external publishing agency were used.

Conflicts of Interest Statement

The authors have no conflicts of interest to declare, and this study did not receive any grant from funding agencies in the public, commercial, or not-for-profit sectors.

Funding Statement

This research did not receive any specific grant from funding agencies in the public, commercial, or not-for-profit sectors.

References

1. Sporer, S. M., Weinstein, J. N., & Koval, K. J. (2006). The geographic incidence and treatment variation of common fractures of elderly patients. *The Journal of the American Academy of Orthopaedic Surgeons*, 14(4), 246–255. <https://doi.org/10.5435/00124635-200604000-00006>
2. Court-Brown, C. M., McBirnie, J., & Wilson, G. (1998). Adult ankle fractures--an increasing problem?. *Acta orthopaedica Scandinavica*, 69(1), 43–47. <https://doi.org/10.3109/17453679809002355>
3. Georgiannos, D., Lampridis, V., & Bisbinas, I. (2017). Fragility fractures of the ankle in the elderly: Open reduction and internal fixation versus tibio-talo-calcaneal nailing: Short-term results of a prospective randomized-controlled study. *Injury*, 48(2), 519–524. <https://doi.org/10.1016/j.injury.2016.11.017>
4. Beauchamp, C. G., Clay, N. R., & Thexton, P. W. (1983). Displaced ankle fractures in patients over 50 years of age. *The Journal of bone and joint surgery. British volume*, 65(3), 329–332. <https://doi.org/10.1302/0301-620X.65B3.6404905>
5. Johnell, O., & Kanis, J. A. (2006). An estimate of the worldwide prevalence and disability associated with osteoporotic fractures. *Osteoporosis international : a journal established as result of cooperation between the European Foundation for Osteoporosis and the National Osteoporosis Foundation of the USA*, 17(12), 1726–1733. <https://doi.org/10.1007/s00198-006-0172-4>

6. Lee, D. O., Kim, J. H., Yoo, B. C., & Yoo, J. H. (2017). Is osteoporosis a risk factor for ankle fracture?: Comparison of bone mineral density between ankle fracture and control groups. *Osteoporosis and sarcopenia*, 3(4), 192–194.
<https://doi.org/10.1016/j.afos.2017.11.005>
7. So, E., Rushing, C. J., Simon, J. E., Goss, D. A., Jr, Prissel, M. A., & Berlet, G. C. (2020). Association Between Bone Mineral Density and Elderly Ankle Fractures: A Systematic Review and Meta-Analysis. *The Journal of foot and ankle surgery : official publication of the American College of Foot and Ankle Surgeons*, 59(5), 1049–1057.
<https://doi.org/10.1053/j.jfas.2020.03.012>
8. Taylor, B. C., Hansen, D. C., Harrison, R., Lucas, D. E., & Degenova, D. (2016). Primary Retrograde Tibiotalocalcaneal Nailing For Fragility Ankle Fractures. *The Iowa orthopaedic journal*, 36, 75–78.
9. O'Daly, B.J., Harty, J.A., O'Malley, N. et al. (2010) Percutaneous Gallagher nail stabilisation for fragility ankle fracture. *Eur J Orthop Surg Traumatol*, 20, 651–655.
<https://doi.org/10.1007/s00590-010-0629-1>.
10. Kanis, J. A., Johnell, O., De Laet, C., Johansson, H., Oden, A., Delmas, P., Eisman, J., Fujiwara, S., Garnero, P., Kroger, H., McCloskey, E. V., Mellstrom, D., Melton, L. J., Pols, H., Reeve, J., Silman, A., & Tenenhouse, A. (2004). A meta-analysis of previous fracture and subsequent fracture risk. *Bone*, 35(2), 375–382.
<https://doi.org/10.1016/j.bone.2004.03.024>
11. Hodsman, A. B., Leslie, W. D., Tsang, J. F., & Gamble, G. D. (2008). 10-year probability of recurrent fractures following wrist and other osteoporotic fractures in a large clinical cohort: an analysis from the Manitoba Bone Density Program. *Archives of internal medicine*, 168(20), 2261–2267. <https://doi.org/10.1001/archinte.168.20.2261>
12. Seeley, D. G., Kelsey, J., Jergas, M., & Nevitt, M. C. (1996). Predictors of ankle and foot fractures in older women. The Study of Osteoporotic Fractures Research Group. *Journal of bone and mineral research : the official journal of the American Society for Bone and Mineral Research*, 11(9), 1347–1355. <https://doi.org/10.1002/jbmr.5650110920>
13. Roux, S., Cabana, F., Carrier, N., Beaulieu, M. C., & Boire, G. (2018). Risk of Subsequent Fragility Fractures Observed After Low-Trauma Ankle Fractures. *Calcified tissue international*, 103(1), 62–70. <https://doi.org/10.1007/s00223-018-0393-5>
14. Valtola, A., Honkanen, R., Kröger, H., Tuppurainen, M., Saarikoski, S., & Alhava, E. (2002). Lifestyle and other factors predict ankle fractures in perimenopausal women: a population-based prospective cohort study. *Bone*, 30(1), 238–242.
[https://doi.org/10.1016/s8756-3282\(01\)00649-4](https://doi.org/10.1016/s8756-3282(01)00649-4)
15. Honkanen, R., Tuppurainen, M., Kröger, H., Alhava, E., & Saarikoski, S. (1998). Relationships between risk factors and fractures differ by type of fracture: a population-based study of 12,192 perimenopausal women. *Osteoporosis international : a journal established as result of cooperation between the European Foundation for Osteoporosis and the National Osteoporosis Foundation of the USA*, 8(1), 25–31.
<https://doi.org/10.1007/s001980050044>
16. Siu, A. L., Penrod, J. D., Boockvar, K. S., Koval, K., Strauss, E., & Morrison, R. S. (2006). Early ambulation after hip fracture: effects on function and mortality. *Archives of internal medicine*, 166(7), 766–771. <https://doi.org/10.1001/archinte.166.7.766>
17. Jordan, R. W., Chapman, A., Buchanan, D., & Makrides, P. (2018). The role of intramedullary fixation in ankle fractures - A systematic review. *Foot and ankle surgery :*

- official journal of the European Society of Foot and Ankle Surgeons, 24(1), 1–10.
<https://doi.org/10.1016/j.fas.2016.04.004>
18. Jonas, S. C., Young, A. F., Curwen, C. H., & McCann, P. A. (2013). Functional outcome following tibio-talar-calcaneal nailing for unstable osteoporotic ankle fractures. *Injury*, 44(7), 994–997. <https://doi.org/10.1016/j.injury.2012.11.008>
 19. Lemon, M., Somayaji, H. S., Khaleel, A., & Elliott, D. S. (2005). Fragility fractures of the ankle: stabilisation with an expandable calcaneotalotibial nail. *The Journal of bone and joint surgery. British volume*, 87(6), 809–813. <https://doi.org/10.1302/0301-620X.87B6.16146>
 20. Kulakli-Inceleme, E., Tas, D. B., Smeeing, D., Houwert, R. M., van Veelen, N. M., Link, B. C., Iselin, L. D., Knobe, M., Babst, R., & Beeres, F. (2021). Tibiototalcalcaneal Intramedullary Nailing for Unstable Geriatric Ankle Fractures. *Geriatric orthopaedic surgery & rehabilitation*, 12, 21514593211020705. <https://doi.org/10.1177/21514593211020705>
 21. Amirfeyz, R., Bacon, A., Ling, J., Blom, A., Hepple, S., Winson, I., & Harries, W. (2008). Fixation of ankle fragility fractures by tibiototalcalcaneal nail. *Archives of orthopaedic and trauma surgery*, 128(4), 423–428. <https://doi.org/10.1007/s00402-008-0584-z>
 22. Al-Nammari, S. S., Dawson-Bowling, S., Amin, A., & Nielsen, D. (2014). Fragility fractures of the ankle in the frail elderly patient: treatment with a long calcaneotalotibial nail. *The bone & joint journal*, 96-B(6), 817–822. <https://doi.org/10.1302/0301-620X.96B6.32721>
 23. Charlson, M., Szatrowski, T. P., Peterson, J., & Gold, J. (1994). Validation of a combined comorbidity index. *Journal of clinical epidemiology*, 47(11), 1245–1251. [https://doi.org/10.1016/0895-4356\(94\)90129-5](https://doi.org/10.1016/0895-4356(94)90129-5)
 24. BOAST. Open Fractures. (2017) <https://www.boa.ac.uk/resources/boast-4-pdf.html>. Accessed: 2 September 2021.
 25. Litchfield J. C. (1987). The treatment of unstable fractures of the ankle in the elderly. *Injury*, 18(2), 128–132. [https://doi.org/10.1016/0020-1383\(87\)90189-6](https://doi.org/10.1016/0020-1383(87)90189-6)
 26. Anand, N., & Klenerman, L. (1993). Ankle fractures in the elderly: MUA versus ORIF. *Injury*, 24(2), 116–120. [https://doi.org/10.1016/0020-1383\(93\)90202-h](https://doi.org/10.1016/0020-1383(93)90202-h)
 27. Buckingham RA, Hepple S, Winson IG. (2000) Outcome of ankle fractures in the elderly. *Foot Ankle Surg*, 6(3):175–178. <https://doi.org/10.1046/j.1460-9584.2000.00213.x>
 28. Srinivasan, C. M., & Moran, C. G. (2001). Internal fixation of ankle fractures in the very elderly. *Injury*, 32(7), 559–563. [https://doi.org/10.1016/s0020-1383\(01\)00034-1](https://doi.org/10.1016/s0020-1383(01)00034-1)
 29. Lynde, M. J., Sautter, T., Hamilton, G. A., & Schuberth, J. M. (2012). Complications after open reduction and internal fixation of ankle fractures in the elderly. *Foot and ankle surgery : official journal of the European Society of Foot and Ankle Surgeons*, 18(2), 103–107.
 30. Ali, M. S., McLaren, C. A., Rouholamin, E., & O'Connor, B. T. (1987). Ankle fractures in the elderly: nonoperative or operative treatment. *Journal of orthopaedic trauma*, 1(4), 275–280. <https://doi.org/10.1097/00005131-198701040-00002>
 31. Testa, G., Ganci, M., Amico, M., Papotto, G., Giardina, S., Sessa, G., & Pavone, V. (2019). Negative prognostic factors in surgical treatment for trimalleolar

- fractures. *European journal of orthopaedic surgery & traumatology : orthopedie traumatologie*, 29(6), 1325–1330. <https://doi.org/10.1007/s00590-019-02430-6>
32. Alswat K. A. (2017). Gender Disparities in Osteoporosis. *Journal of clinical medicine research*, 9(5), 382–387. <https://doi.org/10.14740/jocmr2970w>
33. Houshian, S., Bajaj, S. K., & Mohammed, A. M. (2006). Salvage of osteoporotic ankle fractures after failed primary fixation with an ankle arthrodesis nail: A report on four cases. *Injury*, 37(8), 791–794. <https://doi.org/10.1016/j.injury.2005.08.011>
34. Kim, C., Catanzariti, A. R., & Mendicino, R. W. (2009). Tibiotalocalcaneal arthrodesis for salvage of severe ankle degeneration. *Clinics in podiatric medicine and surgery*, 26(2), 283–302. <https://doi.org/10.1016/j.cpm.2008.12.009>
35. White, C. B., Turner, N. S., Lee, G. C., & Haidukewych, G. J. (2003). Open ankle fractures in patients with diabetes mellitus. *Clinical orthopaedics and related research*, (414), 37–44. <https://doi.org/10.1097/01.blo.0000084402.53464.90>
36. Low, C. K., & Tan, S. K. (1995). Infection in diabetic patients with ankle fractures. *Annals of the Academy of Medicine, Singapore*, 24(3), 353–355.
37. Blotter, R. H., Connolly, E., Wasan, A., & Chapman, M. W. (1999). Acute complications in the operative treatment of isolated ankle fractures in patients with diabetes mellitus. *Foot & ankle international*, 20(11), 687–694. <https://doi.org/10.1177/107110079902001103>
38. Czech, M. P., Tencerova, M., Pedersen, D. J., & Aouadi, M. (2013). Insulin signalling mechanisms for triacylglycerol storage. *Diabetologia*, 56(5), 949–964. <https://doi.org/10.1007/s00125-013-2869-1>
39. Al-Ashhab M. E. (2017). Primary Ankle Arthrodesis for Severely Comminuted Tibial Pilon Fractures. *Orthopedics*, 40(2), e378–e381. <https://doi.org/10.3928/01477447-20161202-04>

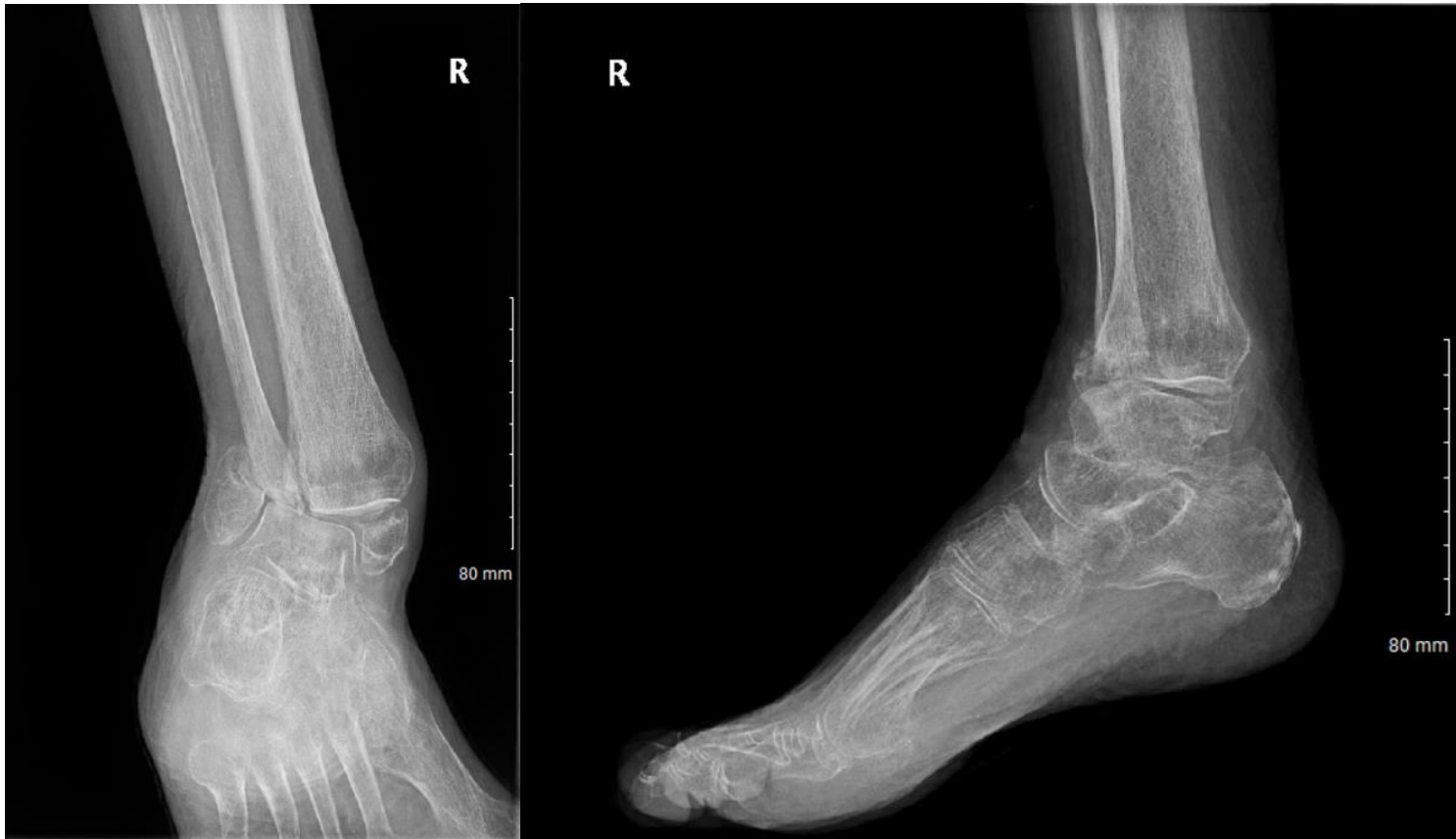

Figure 1: *Left* - AP view before nail insertion in a patient whose joint was prepared; *Right* - Lateral view before nail insertion in a patient whose joint was prepared.

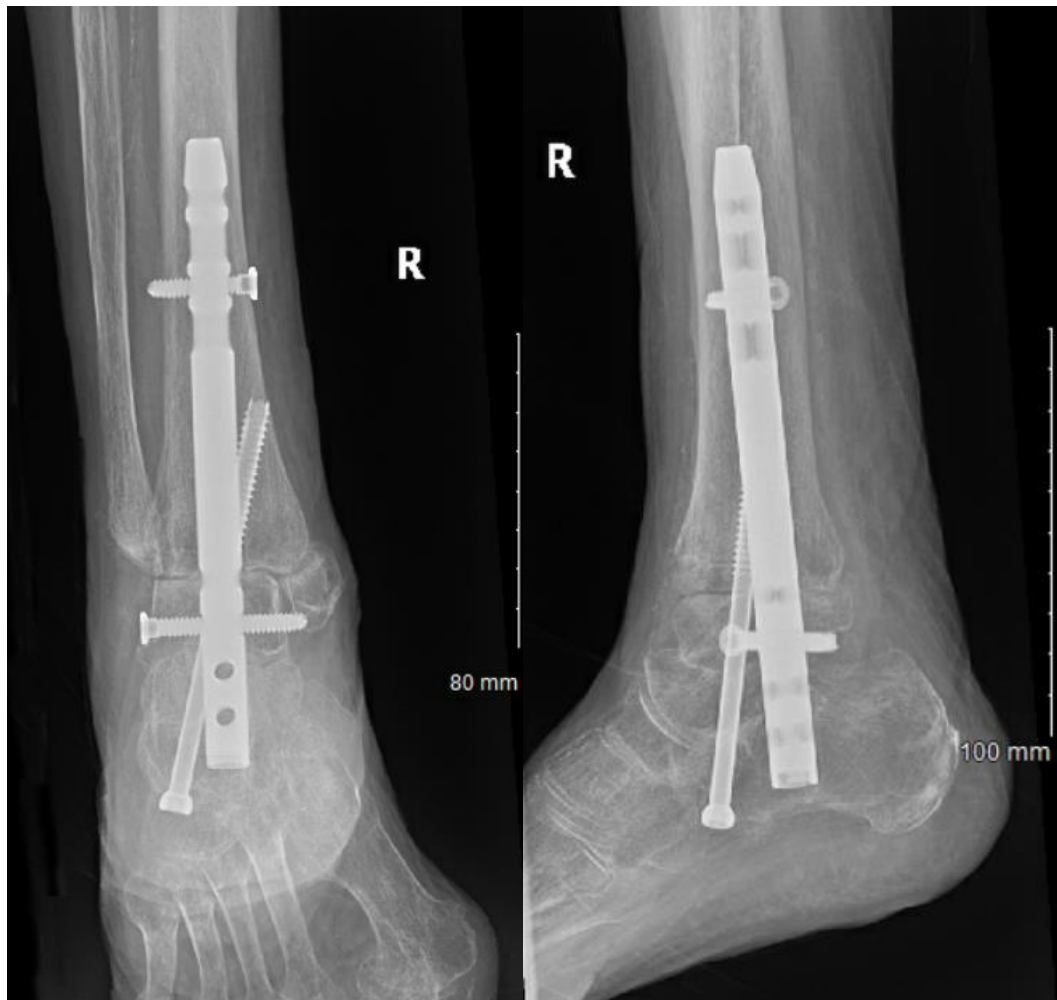

Figure 2: *Left* - AP view after nail insertion with joint preparation; *Right* - Lateral view after nail insertion with joint preparation.

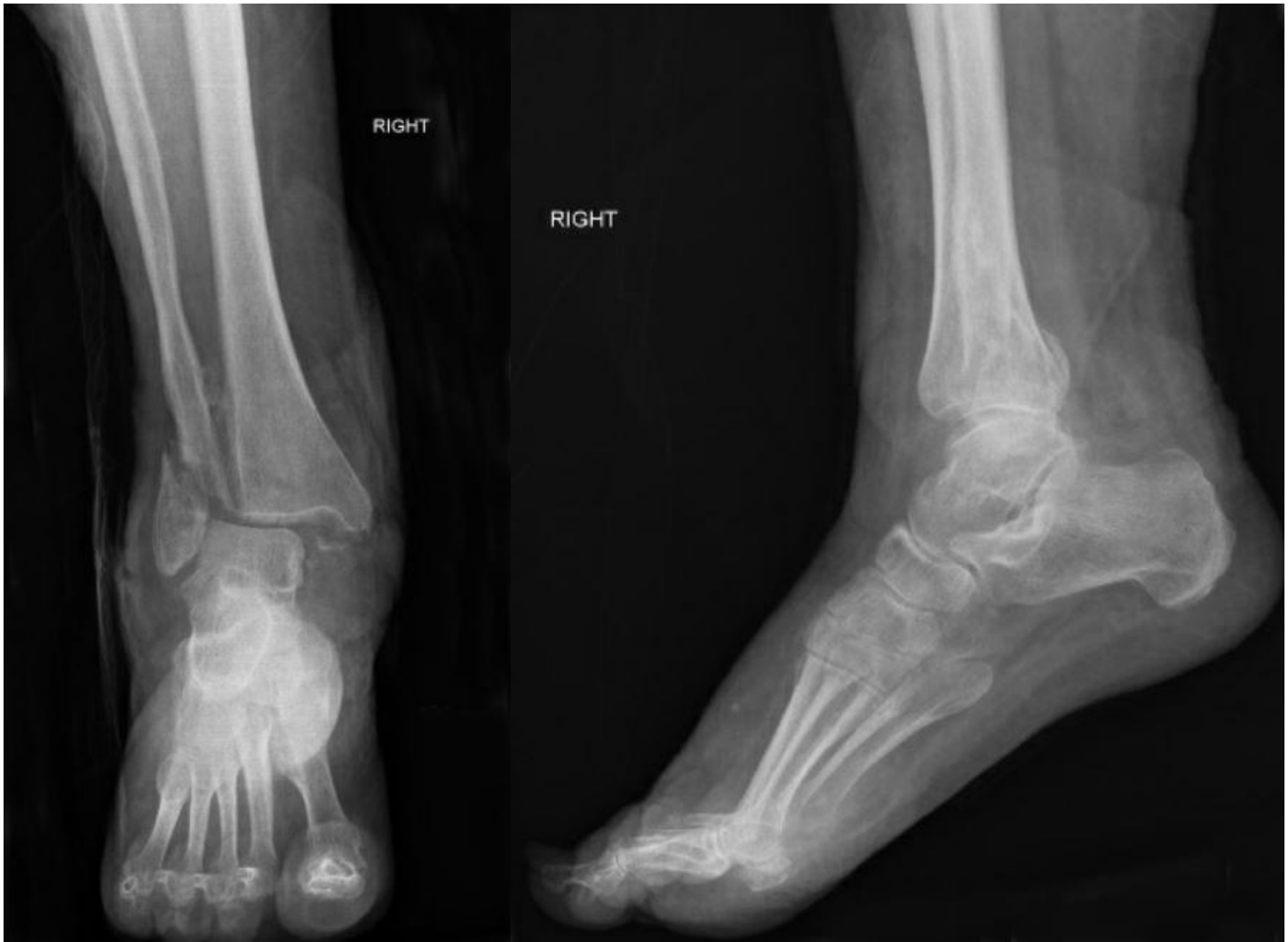

Figure 3: *Left* - AP view before nail insertion in a patient whose joint was not prepared; *Right* - Lateral view before nail insertion in a patient whose joint was not prepared.

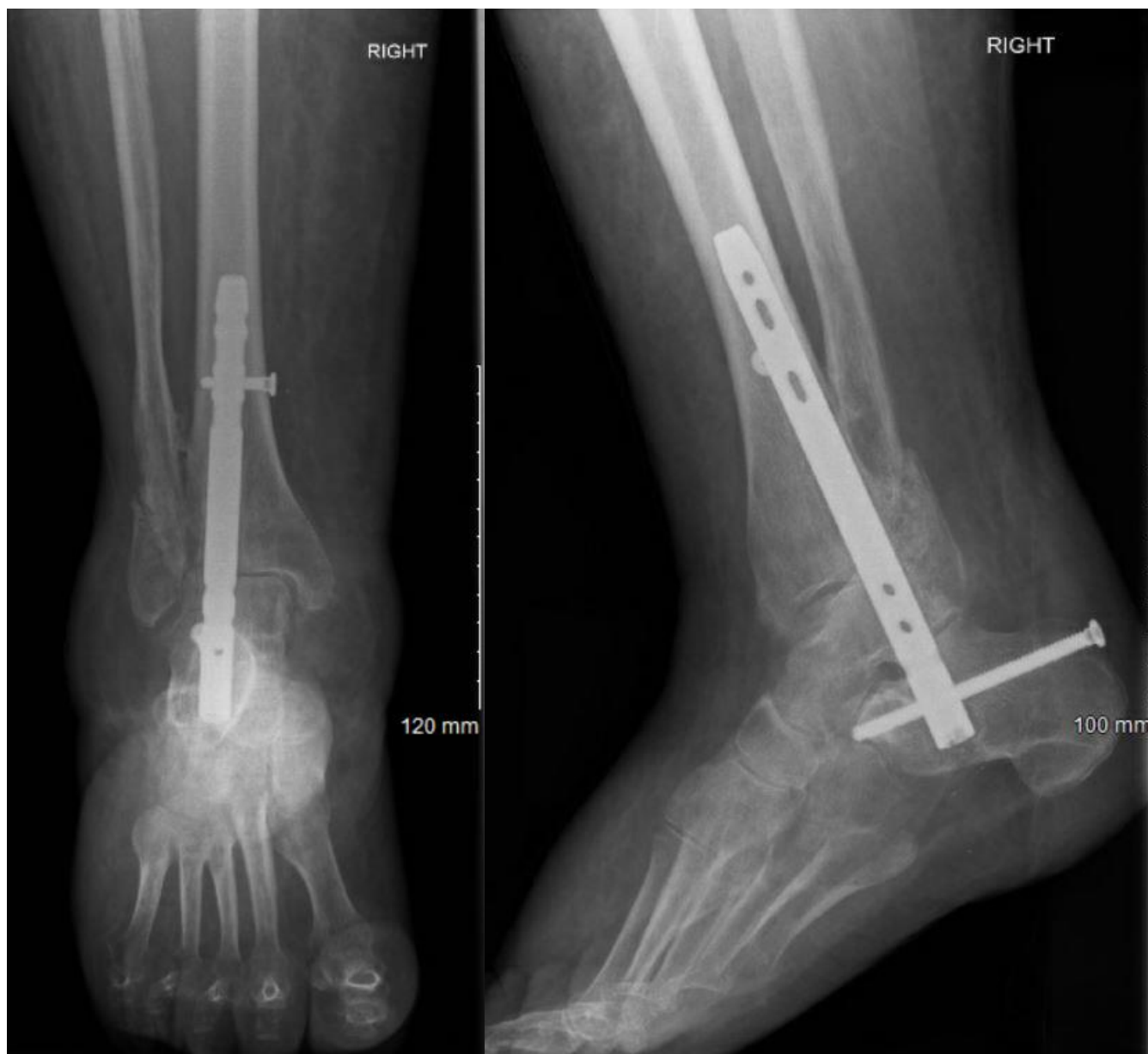


Figure 4: *Left* - AP view after nail insertion with joint not prepared; *Right* - Lateral view after nail insertion with joint not prepared.

Table 1: Patient Demographics

Total Population	20
Male	7 (35%)
Female	13 (65%)
Age (years)	77.82 (61-95)
Male	70.71 (61-95)
Female	82.8 (66-89)
BMI	30.1 (16.65-49.54)
Smoking status	
Ex-smoker	10 (50%)
Non-smoker	8 (40%)
Current smoker	2 (10%)
Diabetes Mellitus	
Yes	5 (25%)
No	15 (75%)
Charlson Comorbidity Index	5.05 (3-9)
ASA Grade	2.44 (2-4)
Fracture Pattern	
Bimalleolar	12 (60%)
Trimalleolar	7 (35%)
Pilon	1 (5%)
Fracture Type	
Closed	11 (55%)
Open Gustilo-Anderson 2	6 (30%)
Open Gustilo-Anderson 3a	2 (10%)
Open Gustilo-Anderson 3b	1 (5%)
Fracture Classification	
AO/OTA 43C1	1 (5%)
AO/OTA 44A2	4 (20%)
AO/OTA 44B1	1 (5%)
AO/OTA 44B2	5 (25%)
AO/OTA 44C1	9 (45%)
Pre-Injury mobility	
Walk independently	5 (25%)
Crutches	7 (35%)
Frame	8 (40%)

Table 2: Clinical Outcomes


Time to Mobilisation (days)	7.6 (2-24)
Bone Union Time Interval (days)	92.5 to 144.6
Hospital length of stay (days)	10.8 (2-31)
Average operative time (min)	131.2 (68-227)
Average follow-up time (days)	499.3 (51-1360)
Post-operative complications	8 (40%)
Deaths within 6 months	3 (15%)
AOFAS score 6 months after operation	53.0 (17-88)
Olerud-Molander score 6 months after operation	50.9 (20-85)
Mobility 12 months after operation	
Walk independently	0
Crutches	6 (30%)
Frame	12 (60%)
Wheelchair	2 (10%)




[Click here to access/download](#)

Supplementary Material

EJOST Ankle Fusion Cover Letter.docx







[Click here to access/download](#)

Supplementary Material

EJOST ankle fusion conflict of interest form.pdf





[Click here to access/download](#)

Supplementary Material
EJOST Manuscript Track Changes.docx



Ankle Fusion with Tibiotalocalcaneal Retrograde Nail for Fragility Ankle Fractures: Outcomes at a Major Trauma Centre

*Victor Lu^{*1}, Maria Tennyson², James Zhang¹, Azeem Thahir², Andrew Zhou¹, Matija Krkovic²*

¹School of Clinical Medicine, University of Cambridge, CB2 0SP, United Kingdom

²Department of Trauma and Orthopaedics, Addenbrooke's Hospital, CB2 0QQ, United Kingdom

** Corresponding author. Email: victorluwawa@yahoo.com.hk Postal address: Christ's College, St. Andrew's Street, Cambridge, CB2 3BU*

Email addresses

victorluwawa@yahoo.com.hk (V.L.); ORCID: 0000-0002-6818-1683

maria.tennyson@addenbrookes.nhs.uk (M.T.)

zz357@cam.ac.uk (J.Z.); ORCID: 0000-0002-2965-8709

azeem.thahir@addenbrookes.nhs.uk (A.T.); ORCID: 0000-0003-3394-9418

azhou1998@icloud.com (A.Z.); ORCID: 0000-0001-6656-8123

matija.krkovic@addenbrookes.nhs.uk (M.K.); ORCID: 0000-0003-2172-2849

Declarations

Funding: The authors did not receive support from any organization for the submitted work.

Conflict of Interest: The authors have no conflicts of interest to declare that are relevant to the content of this article.

Availability of data and material: The authors confirm that the data supporting the findings of this study are available within the article [and/or] its supplementary materials.

Authors' Contributions: V.L wrote the manuscript; V.L, M.T., J.Z., A.T. A.Z. performed data collection; M.T., J.Z., A.T. A.Z. reviewed previous drafts of the manuscript; M.K. designed this study, and reviewed previous drafts of the manuscript.

Ethics approval: This study was approved by the clinical research department (PRN9832).

Consent to participate: All included patients consented to participate in this study.

Consent to publication: All authors have reviewed the final version and have consented to publication.