

FUNCTIONAL NEUROIMAGING FINDINGS IN HEALTHY MIDDLE-AGED ADULTS AT RISK OF ALZHEIMER'S DISEASE

Mirette Habib^{1*}, Elijah Mak^{2*}, Silvy Gabel², Li Su², Guy Williams³, Adam Waldman⁴, Katie Wells¹, Karen Ritchie^{6,7}, Craig Ritchie⁵, John T O'Brien²

* Both authors contributed equally to the work.

¹ The Centre for Mental Health, Imperial College London, UK., ² Department of Psychiatry, School of Clinical Medicine, Addenbrooke's Hospital, University of Cambridge, UK., ³ Wolfson Brain Imaging Centre, University of Cambridge, UK., ⁴ Centre for Clinical Brain Sciences, University of Edinburgh, UK., ⁵ Centre for Dementia Prevention, University of Edinburgh, UK., ⁶ INSERM Unit 1061 Neuropsychiatry, ⁷ Faculty of Medicine, University of Montpellier.

Corresponding author:

Prof John O'Brien

Foundation Professor of Old Age Psychiatry

Department of Psychiatry

University of Cambridge School of Clinical Medicine

Box 189, Level E4 Cambridge Biomedical Campus

Cambridge

CB2 0SP

UK

Abstract word count: 286

Manuscript word count: 4780

ABSTRACT

It is well established that the neurodegenerative process of Alzheimer's disease (AD) begins many years before symptom onset. This preclinical phase provides a crucial time-window for therapeutic intervention, though this requires biomarkers that could evaluate the efficacy of future disease-modification treatments in asymptomatic individuals. The last decade has witnessed a proliferation of studies characterizing the temporal sequence of the earliest functional and structural brain imaging changes in AD. These efforts have focused on studying individuals who are highly vulnerable to develop AD, such as those with familial genetic mutations, susceptibility genes (i.e. apolipoprotein epsilon-4 allele), and/or a positive family history of AD. In this paper, we review the rapidly growing literature of functional imaging changes in cognitively intact individuals who are middle-aged: positron emission tomography (PET) studies of amyloid deposition, glucose metabolism, as well as arterial spin labeling (ASL), task-dependent, resting-state functional magnetic resonance imaging (fMRI) and magnetic resonance spectroscopy (MRS) studies. The prevailing evidence points to early brain functional changes in the relative absence of cognitive impairment and structural atrophy, although there is marked variability in the directionality of the changes, which could, in turn, be related to antagonistic pleiotropy early in life. A common theme across studies relates to the spatial extent of these changes, most of which overlap with brain regions that are implicated in established AD. Notwithstanding several methodological caveats, functional imaging techniques could be preferentially sensitive to the earliest events of AD pathology prior to macroscopic grey matter loss and clinical manifestations of AD. We conclude that while these techniques have great potential to serve as biomarkers to identify at-risk individuals, more longitudinal studies with greater sample size and robust correction for multiple comparisons are still warranted to establish their utility.

Search terms: Alzheimer's disease, neurodegeneration, preclinical dementia, functional, magnetic resonance imaging, positron emission tomography, neuroimaging, cognitive impairment.

INTRODUCTION

There are now 46 million people living with dementia, and the number is expected to rise to 115 million in 2050 (World Alzheimer Report 2015). Dementia is a relatively late feature in the pathophysiology of Alzheimer's disease (AD), with pathological changes beginning decades before symptom onset (Jack et al., 2013). Therefore, the identification of individuals prior to the onset of significant clinical symptoms is an important prerequisite for the initiation of earlier treatments, particularly as they are likely to have the greatest potential for delaying symptom onset and slowing down cognitive decline at the earliest disease stages.

Biomarkers in clinical medicine are used to predict or detect specific illnesses, monitor disease progression, and predict response to treatment. The search for biomarkers to detect early neurodegenerative changes preclinically includes the exploration of structural neuroimaging (Mak et al., 2016a), functional neuroimaging (Wierenga & Bondi, 2007), genomics, proteomics, neurophysiology, cerebrospinal fluid (CSF), and blood analysis (Van Steenoven et al., 2016). Over the past decade, a variety of imaging techniques which probe brain function have been used to investigate early pathological changes in individuals at risk of developing AD. Research participants included those with a family history of AD, carriers of apolipoprotein epsilon-4 allele (ApoE4) and autosomal-dominant or familial AD (FAD) mutations in the genes of presenilin 1 (PSEN1), PSEN2 and amyloid precursor protein (APP). Given the close relationships between the presence of these risk factors and AD, studying these individuals provide an invaluable opportunity to chart the natural trajectory of disease progression in AD (Ritchie & Ritchie, 2012).

As a two-part systematic review, we have recently surveyed the structural imaging changes in preclinical dementia (Mak et al., 2016a). As change in brain morphology is often a late event in the neurodegenerative cascade, changes detectable with functional imaging may precede grey matter

atrophy and white matter degeneration. The term functional MRI (fMRI) has become associated specifically with blood oxygen level dependent BOLD imaging; for the purposes of this review, however, we will consider a broader definition of functional imaging to include techniques which yield information on physiology and specific pathological processes as well as function. We will review the literature concerning functional imaging studies in middle-aged asymptomatic subjects under the age of 60 to survey subtle changes that arise years and even decades prior to the manifestations of cognitive decline. Findings will be drawn from (a) positron emission tomography (PET) studies of amyloid burden (^{11}C -PIB or ^{18}F compounds), cerebral glucose metabolism (b) perfusion MRI and task-based and resting-state functional magnetic resonance (fMRI) and (c) magnetic resonance spectroscopy (^1H MRS). These techniques could have prognostic utility for identifying those at risk, predicting and monitoring disease progression and potentially the evaluation of a broad range of therapeutic interventions encompassing life-style changes, dietary improvements, and disease modifying therapies.

METHOD

The literature search used to obtain articles for the purpose of this review was done by searching Medline and PubMed, using key words, “preclinical” and “dementia” and “functional” and “neuroimaging” and “Florbetapir”, “Flumetamol”, “Florbetapen”, “Magnetic Resonance Spectroscopy”, “functional MRI”, “FDG-PET” and “PIB”. Other terms included “brain”, “imaging”, “resting-state”, “healthy”, “young” and “middle-aged”. Articles included were from the year 1990 till April 2016. We only considered human studies in English language. Articles had to describe the association between a known risk factor for dementia and neuroimaging changes or had to follow up a cohort originating in midlife or earlier with imaging undertaken at a later stage. Only studies involving functional neuroimaging modalities (PET and MRI) were included in this review. Relevant citations from the reference lists of identified articles were also reviewed.

POSITRON EMISSION TOMOGRAPHY

Amyloid deposition

The advent of PET amyloid ligands has enabled the *in vivo* investigation of fibrillar amyloid deposition, heralding a rapidly growing literature in both AD and its preclinical stages (see Rabinovici & Jagust, 2009 for a review). The first ligand with high specificity for amyloid was the ^{11}C -Pittsburgh Compound B (^{11}C -PIB) (Klunk et al., 2004). Subsequently, three other ^{18}F based amyloid ligands have been developed and licensed for clinical use (^{18}F -florbetapir, ^{18}F -florbetaben and ^{18}F -flutemetamol) (O'Brien & Herholz, 2015). Several studies have reported strong agreement in uptake measures among the different PET amyloid ligands (Villemagne et al., 2012).

In AD, the topography of amyloid follows a diffuse pattern with the prefrontal cortices, precuneus and posterior cingulate cortex being the earliest sites of vulnerability (Rabinovici & Jagust, 2009; Thal et al., 2002). In preclinical dementia, there is some evidence to suggest a distinct topographical pattern of amyloid (Figure 1A). In the first *in vivo* investigation of amyloid deposition in asymptomatic PSEN1 mutation carriers (~10 years before expected onset of cognitive symptoms), Klunk and colleagues reported preferential PIB binding to the striatal regions (Klunk et al., 2007). The *in vivo* findings were corroborated by histological evidence showing that the density of plaques in the striatum exceeded that of the cortex and subsequently confirmed by another study involving 7 PSEN1 mutation carriers and 1 APP mutation carrier (Villemagne et al., 2009). These *in vivo* findings have prompted the hypothesis that the striatum is one of the earliest sites of amyloid deposition (Klunk et al., 2007), thereby challenging the notion that striatal plaques only occur at later histopathological stages (i.e. second phase of amyloid deposition) in AD (Braak & Braak, 1990; Thal et al., 2002). Others have reported increased amyloid burden in the adjacent thalamus and the cerebellum in asymptomatic FAD mutation carriers (Knight et al., 2011; Villemagne et al., 2009).

However, doubts remain over the universality of striatal amyloid across in FAD (Fleisher et al., 2012; Knight et al., 2011). The clinical relevance of PIB retention in FAD is still ambiguous. In Villemagne et al (2009), the patterns of PIB retention in both striatal and neocortical regions were not associated with disease severity or cognitive function. Neither were there significant differences in amyloid burden between dichotomized subgroups of Mini Mental State Examination (MMSE) scores (> 20 or ≤ 20) and Clinical Dementia Rating (CDR) (>2 or ≤ 2).

More recent studies from the Dominantly Inherited Alzheimer's Network study (DIAN) – a large-scale investigation of MRI and PET data in FAD mutation carriers – have implicated the precuneus as an early site of amyloid burden, approximately up to 15 years before expected symptom onset (Bateman et al., 2012). These findings are in accordance with those from the Colombian Alzheimer's Prevention Initiative Registry (API), which includes more than 1500 living members from the largest known autosomal-dominant AD kindred, 30% of whom are carriers of the PSEN1 *E280A* mutation (Lopera et al., 1997). A unique trait of the Columbian kindred is that it represents the most genetically and ethnically homogenous sample from the same geographical location. Fleisher and colleagues (2012) characterized the pattern of fibrillar amyloid deposition and estimated its temporal relation with clinical onset among 30 PSEN1 mutation carriers (20 – 56 years of age) and 20 asymptomatic non-carriers. Using a voxel-wise approach, asymptomatic mutation carriers ($n=19$) demonstrated increased ^{18}F florbetapir binding in widespread regions encompassing the precuneus, cingulate regions, temporoparietal regions, frontal grey matter and the basal ganglia (Fleisher et al., 2012). Notably, these findings remained significant after controlling for atrophy and partial volume adjustments. Consistent with data from the DIAN study (Bateman et al., 2012), the trajectory of amyloid deposition was estimated to follow a steep acceleration (16 and 21 years before mild cognitive impairment (MCI) and AD respectively) before slowing to a plateau before the estimated age of onset.

The Australian Imaging Biomarkers and Lifestyle (AIBL) study reported that 49% of ApoE4 carriers were found to be ^{11}C -PIB positive in contrast to 21% among non-carriers (Rowe et al., 2010). In cognitively normal older subjects, the presence of ApoE4 has been associated with both increased and earlier amyloid deposition (Fleisher et al., 2013; Morris et al., 2010) as well as 3-fold increased odds of amyloid positivity (Mielke et al., 2012). Data from the Adult Children Study (ACS) cohort involving middle-older age individuals (stratified by family history for AD) have shown an age-related increase in mean cortical binding potential of PIB-PET that was associated with ApoE4 but *not* family history. Furthermore, the younger group (age < 55) did not show any significant associations between mean cortical binding potential (MCBP) with other CSF biomarkers and brain volumes (Xiong et al., 2011).

Cerebral glucose metabolism

The ^{18}F 2-fluorodeoxy-D-glucose (FDG) PET tracer has been used to quantify aberrant cerebral metabolic rate of glucose in AD (Minoshima et al., 1997, 1995; see Schubert, 2005 for a review) In general, preclinical AD appears to be characterized by a hypometabolic profile in temporo-parietal cortices including the precuneus. In a study of 235 volunteers aged 50 – 65 years old with a positive family history of AD, 11 ApoE4 homozygotes were compared against 22 non-ApoE4 carriers. Despite being cognitively intact, the ApoE4 carriers had significantly decreased glucose metabolism in regions that are often affected in AD, including the posterior cingulate, temporo-parietal and prefrontal regions (Reiman et al., 1996). Of note, the posterior cingulate and precuneus were the most hypometabolic regions (Figure 1B), in line with AD studies where it is regarded as a site of confluence for various pathologies including amyloid deposition, cortical atrophy and hypometabolism (Buckner et al., 2005). These findings in middle-aged ApoE4 carriers were subsequently extended to a younger sample of ApoE4 heterozygotes well before midlife (n = 12;

20 – 39 years of age) (Reiman et al., 2004). Furthermore, the pathological relevance of these regional metabolic deficits was supported by a dose-dependent correlation between ApoE4 (none, one, or two copies) in the posterior cingulate cortex among middle-aged persons. The authors also demonstrated that the relationship was significantly stronger compared to that of hippocampal glucose metabolism or volume (Fisher's *R* to *Z* test). These collective findings suggest that posterior cingulate hypometabolism appear to anticipate MTL atrophy and provide further evidence that functional imaging techniques might be more sensitive to subtle alterations in the early stages of the disease.

In one of the few longitudinal studies, Reiman and colleagues investigated the progression of hypometabolism in 10 cognitively normal ApoE4 carriers (50 – 63 years of age) over 2 years. Compared to non-carriers, ApoE4 carriers showed significantly more severe metabolic deficits over time in the posterior cingulate, fronto-temporal cortices as well as basal forebrain and the thalamus (Reiman et al., 2001).

Several studies have also demonstrated focal temporo-parietal metabolic deficits in FAD mutation carriers (Fleisher et al., 2015; Kennedy et al., 1995). Kennedy and colleagues showed an intermediate level of cerebral glucose metabolism in presymptomatic individuals between controls and symptomatic FAD carriers, whereas decreased metabolism in the precuneus was found in presymptomatic PSEN1 carriers from the Columbian kindred (Fleisher et al., 2015). However, despite the consistent literature indicating hypometabolism in preclinical AD, the associations or differential contributions of FDG-PET and structural brain atrophy remains poorly understood. To address this question, Mosconi and colleagues conducted a multi-modal study of FDG-PET and MRI in a sample of 7 asymptomatic PSEN1 carriers (age: 35 – 49) (Mosconi et al., 2006). From a methodological perspective, this is one of the few studies in the literature that has corrected the

PET scans for partial volume effects (2 segment model of brain tissue and CSF). This is critical in FDG-PET studies because the extent of atrophy will artificially dilute of PET measurements, thus inflating the degree of hypometabolism in vulnerable regions and accentuating the group-differences between carriers and non-carriers. Using the ROI approach to enable direct comparisons of atrophy and hypometabolism, the authors reported convincing evidence of hypometabolism in the MTL in the relative absence of atrophy. In addition, FDG-PET measurements were less variable than the MRI-based volume measurements, in turn resulting in stronger discriminatory sensitivity in the preclinical AD stage. Given that hypometabolism is thought to reflect synaptic dysfunction, these findings indicate that FDG-PET imaging could be more sensitive to such alterations that typically precede macroscopic grey matter atrophy.

FUNCTIONAL MAGNETIC RESONANCE IMAGING

Arterial spin labeling

Arterial spin labeling (ASL) is a non-invasive MRI technique for the measurement of cerebral perfusion and it is emerging as another promising biomarker in the early stages of AD (see Hays et al., 2016 for a review). While cerebral glucose metabolism has been traditionally measured using radionuclide imaging as previously described (FDG-PET), its widespread utility has largely been mitigated by limited availability, radiation exposure and costs associated with nuclear imaging. In contrast, ASL provides a measure of cerebral blood flow (CBF) by using magnetically labeled arterial blood water as an endogenous tracer. Its increasing use has been supported by showing a high degree of agreement with FDG-PET (Musiek et al., 2012). Other advantages include (a) greater accessibility, (b) cheaper cost of MRI compared to PET, (c) safety benefits (i.e. free of exposure to ionizing radiation and intravenous contrast agent and (d) simultaneous acquisition within a structural MRI session (~ 6 – 10 minutes).

At present, there are relatively fewer ASL studies in preclinical AD, particularly in the young to middle-age groups. A previous study reported that resting CBF – particularly in the MTL – was markedly *increased* (24%) in middle-aged individuals with ApoE4 and family history of AD. Interestingly, the at-risk group showed the opposite effect of *reduced* CBF in the MTL when challenged with an associative encoding task. The phenomena of increased baseline CBF was interpreted by the authors to represent a global compensatory mechanism to sustain activity in functionally impaired regions (Fleisher et al., 2009). These findings are in agreement with another study of individuals stratified according to maternal or paternal family history. Echoing previous findings where maternal history was associated with a more severe neurodegenerative profile (Okonkwo et al., 2012), the authors found that individuals with a maternal history of AD showed greater hypoperfusion in the hippocampal and fronto-parietal regions compared to both controls as well as individuals with a paternal family history of AD. The significance of these group differences also persisted after voxel-wise correction for grey matter atrophy. These findings are also consistent with a previously described FDG-PET study (Mosconi et al., 2009), and together add to a growing body of evidence implicating maternal family history of AD in greater cognitive decline (DeBette et al., 2009).

Others have demonstrated differential impact of ApoE4 on resting CBF across the lifespan (Wierenga et al., 2013). While older ApoE4 (age = 75) adults showed decreased CBF in widespread regions, younger ApoE4 (age = 24) had increased perfusion particularly in the anterior cingulate cortex, which was, in turn, correlated with executive function (Figure 1C). However, other studies have not found any difference between young ApoE4 carriers (age = 28) and non-carriers (age = 29) (Filippini et al., 2009). These inconsistencies could be attributed to the different methodological approaches. In contrast to the whole brain voxel-wise approach (Wierenga et al., 2013), an ROI-based analysis was used in Filippini et al to restrict CBF comparisons to the hippocampus, midbrain

and cerebellum. As such, any focal or subtle ApoE4 signal at the voxel-level may have been masked out by the averaging of voxels across the ROIs.

Task-based fMRI

fMRI offers considerable promise as a non-invasive technique that is sensitive to early functional changes in asymptomatic individuals. It provides an indirect measure of neuronal activity through the inference of changes in blood oxygen level dependent (BOLD) fMRI signal (Logothetis, 2008). Task-based fMRI studies typically compare BOLD signals that are evoked during one condition (i.e. remembering a word stimuli) to BOLD signals associated with a baseline condition or control task.

ApoE4 carriers have shown reduced hippocampal and MTL activations during task performance involving episodic encoding, visual naming and letter fluency (Nichols et al., 2012; Smith et al., 1999; Trivedi et al., 2006). However, decreases in functional activation have not been universally reported in ApoE4 carriers (Dennis et al., 2010; Filippini et al., 2009; Quiroz et al., 2010). For instance, hippocampal hyperactivity has been evoked during encoding in younger ApoE4 carriers (age = 28), independent of grey matter atrophy and perfusion changes (Figure 1D). These findings are in parallel with those of Dennis et al (2010), where young ApoE4 carriers (age = 23.2) also exhibited MTL hyperactivation during encoding despite comparable memory performance and grey matter volumes relative to non-carriers (Dennis et al., 2010). These reports, taken together with previous ASL studies in younger ApoE4 carriers, add further support to the notion that the role of ApoE4 is not uniform across the life-span. Based on the young age of the sample and the lack of behavioral differences between groups, MTL hyperactivity in ApoE4 carriers could be interpreted as inefficient processing associated with dysfunction in the medial temporal lobe or compensatory processing necessary to achieve similar cognitive output to that in non-carriers (Dennis et al., 2010). Interestingly, the interactions between ApoE4 allele and functional changes in young adults may

also be modulated by the difficulty of the task in question (Chen et al., 2013). Notwithstanding the caveats of a small sample size ($n = 9$ in each group) and lenient statistical thresholding ($p < 0.01$ uncorrected), Chen and colleagues showed that low-load working memory tasks (N-Back) evoked hyperactivation in ApoE4 carriers, although this effect was diminished with increasing working memory load. In contrast, non-carriers continued to show increasing levels of functional activity during the moderate and higher working memory levels of the task.

Task-based functional changes have also been investigated in FAD mutation carriers (Braskie et al., 2013; Mondadori et al., 2006; Quiroz et al., 2010; Ringman et al., 2011). In a previous study of an FAD family ($n = 5$, estimated age of clinical manifestation = 48 years), a young PSEN1 mutation carrier (age = 20) also showed hyperactivation in memory-related networks during episodic learning and retrieval tasks compared to controls (Mondadori et al., 2006). Conversely, weaker activations were observed in the middle-aged mutation carrier, who has an amnesic MCI profile (age = 45). Although these findings were not corrected for atrophy, the authors noted that manually-segmented MTL volumes were comparable between the FAD family members and the controls. These findings, albeit restricted to 2 PSEN1 carriers, were later supported by a larger study of the Columbian kindred ($n = 20$ carriers, age = 33) (Quiroz et al., 2010). Despite exhibiting similar cognitive profiles and preserved hippocampal volumes compared to controls, the young PSEN1 carriers showed hippocampal hyperactivation during encoding tasks of novel associations. These findings are in agreement with observations of decreased parietal inhibition during a memory encoding task in the youngest group of PSEN1 carriers studied to date ($n = 19$, age = 14) (Quiroz et al., 2015). Overall, the findings of hyperactivation – indicative of functional dysregulation – in young at-risk individuals bear resemblance to previous reports in MCI and AD (Dickerson et al., 2005), and collectively fit with the model that postulates a transient phase of functional hyperactivation followed by a steep

decrease in functional activation as neuronal populations gradually lose their ability to engage in compensatory mechanisms (Dickerson et al., 2005).

Resting-state fMRI studies

Resting-state fMRI (RS-fMRI) is a relatively recent technique to investigate spontaneous low-frequency fluctuations in BOLD signals. In rsfMRI studies, subjects are asked to rest with their eyes closed or fixated on a cross-hair. The spontaneous temporal correlations are thought to be manifestations of intrinsic functional connectivity across brain networks (RSNs) (Biswal et al., 1995), which could be interrogated with seed-based or data-driven independent component analyses (Beckmann, 2005).

The effects of ApoE4 on brain networks have been increasingly studied in preclinical AD, revealing functional alterations in overlapping brain regions that are disrupted in AD (Sheline & Raichle, 2013). Of particular interest is the default mode network (DMN), which was first described by Raichle and colleagues using PET data (Gusnard & Raichle, 2001; Raichle et al., 2001). The DMN encompasses the midline, frontal, MTL and parietal regions as well as the posterior cingulate cortex (Buckner et al., 2005). A growing body of evidence has implicated the DMN across the spectrum from normal aging to MCI and AD (Buckner et al., 2005; Lustig et al., 2003). The relevance of the DMN in the pathophysiology of dementia is also supported by the observations that its constituent regions are often the sites of early and focal atrophy, reduced perfusion/metabolism as well as fibrillary amyloid deposition (Buckner et al., 2005; Jack et al., 2013; Klunk et al., 2004). Therefore, the failure to suppress the DMN during task engagement may prove to be a promising biomarker for earlier identification of AD pathology.

Abnormal DMN connectivity has been described among ApoE4 (Fleisher et al., 2009; Goveas et al., 2013; Patel et al., 2013) and FAD mutations carriers (Chhatwal et al., 2013). A previous study of presymptomatic ApoE4 carriers also reported decreased DMN connectivity in the absence of amyloid burden (Sheline et al., 2010) (Figure 1D). Indeed, a key strength of this study was the use of *in vivo* amyloid PET imaging to (a) identify PIB-positive or negative individuals before (b) substratification into those with and without an ApoE4 allele, thereby allowing the authors to determine whether the functional effects of ApoE4 is independent of the cardinal initiating event in AD (Bloom, 2014).

Consistent with earlier suggestions of an antagonistic pleiotropic effect of the ApoE4 allele (Wierenga et al., 2013), younger ApoE4 carriers have shown hippocampal hyperconnectivity within the DMN in the absence of cognitive deficits, structural atrophy and hypoperfusion (age range: 20 – 35 years) (Filippini et al., 2015). Another study has investigated a potential gender-ApoE4 interaction, revealing decreased functional connectivity between the hippocampus and the DMN in female carriers (Heise et al., 2014). There is also emerging evidence that resting-state analyses may be more sensitive than task-based fMRI to early perturbations in preclinical AD, as evidenced by a larger effect size (3.35 vs 1.39) in distinguishing asymptomatic at-risk individuals (ApoE4 and positive family history) from controls (Fleisher et al., 2009). There are several advantages of resting-state fMRI: (a) independence from task performance, which could be influenced by multiple factors unrelated to the underlying disease (i.e. interpretation of task demands, motivation and cognitive fluctuations); (b) ease of standardization across multi-site studies, (c) data collection from patients with substantial cognitive impairment (i.e. avoidance of floor effects); (d) ability to investigate multiple RSNs from the same datasets as opposed to unique experimental paradigms that are catered to specific cognitive domains.

MAGNETIC RESONANCE SPECTROSCOPY

In vivo ^1H MRS allows non-invasive biochemical quantification in defined regions of the brain, and characteristic metabolite changes have been recognized in AD and other dementias since the early 1990's (Graff-Radford et al., 2014). Multiple metabolites, each thought to reflect different cellular and molecular aspects of the neurodegenerative process, can be measured during a single acquisition: (a) N-acetylaspartate (NAA) is a marker of neuronal integrity; (b) myoinositol (ml) levels are thought to predominantly reflect glial activation; (c) Choline containing compounds (Cho) are associated with membrane turnover and inflammatory processes; and metabolite levels are frequently expressed as ratios to creatine/phosphocreatine (Cr). Although a substantial literature exists in dementia and MCI, there are currently relatively few studies in the asymptomatic stages of AD. In the Columbian kindred described previously, variations of ^1H MRS measurements in the posterior cingulate and precuneus have been shown to separate asymptomatic PSEN1 mutation carriers from non-carriers with high accuracy (Londono et al., 2014). Another study demonstrated decreases in the posterior cingulate NAA/Cr and NAA/ml among presymptomatic PSEN1/APP mutation carriers ($n = 7$). In addition, the magnitude of these deficits were correlated with the proximity of expected age of onset (Godbolt et al., 2006). Despite the scarcity of ^1H -MRS studies in FAD mutation carriers, there is convergent evidence that lower NAA/Cr in the posterior cingulate increases the risk of dementia in MCI (Kantarci et al., 2009). Taken together, these studies provide important evidence that metabolic changes, particularly within the posterior cingulate and precuneus (Figure 1E), can be detected in presymptomatic mutation carriers before the emergence of cognitive impairment.

CAVEATS AND METHODOLOGICAL CONSIDERATIONS

Studying younger subjects at risk of familial AD has the advantage of eliminating or reducing the effects of other age-related comorbidities (e.g. hypertension) that may play a confounding role in

cerebral pathology (e.g. ischemic changes). However, there are limitations to the degrees in which the findings in FAD are both (a) consistent and (b) generalizable to sporadic late onset AD, which could in turn hamper efforts to detect treatment effects due to a suboptimal choice of biomarker. There is also a scarcity of longitudinal functional studies, precluding definitive conclusions about the ability of the functional imaging techniques to track disease progression. To date, most cross-sectional studies in FAD mutation carriers have calculated the “estimated age of onset” (EOY) in presymptomatic carriers, but it is essentially just a *construct* to determine biomarker changes as a function of an individual’s position along the trajectory of disease course. The validity of EOY is inherently limited by many factors including the assumption that the parental age of onset is an accurate approximation for the offspring carriers. Future prospective longitudinal studies are thus required to follow asymptomatic FAD carriers to the symptomatic stages to confirm the predictive validity of functional changes. In anticipation of future longitudinal studies, the present FAD findings could ideally be compared against cohorts of cognitively-normal at-risk individuals, such as those from the Alzheimer’s Disease Neuroimaging Initiative (ADNI), Australian Imaging Biomarkers and Lifestyle (AIBL), WRAP (7 – 10 years of multimodal imaging data). The PREVENT study (Ritchie & Ritchie, 2012), which is an on-going study from our group, is also collecting large amounts of imaging data (including MRI, DTI, MRS and fMRI) from people aged 40 to 59 at baseline, as well as detailed neuropsychological assessment using the COGNITIO test battery (Ritchie et al., 2014) designed for pre-clinical cognitive assessment as well as genetic analyses.

In our review, most studies have not performed partial volume correction, opting instead to (a) include grey matter volume as a covariate and/or (b) establish the relative absence of grey matter atrophy. While these statistical adjustments are improvements over the lack of PVC, grey matter volumes are usually collinear with other covariates of interest such as age. It is imperative that future functional studies account for grey matter atrophy which could exacerbate the spillover

contamination of PET/fMRI data. Due to the poor spatial resolution of PET and fMRI data, the intensity of a given voxel will be an aggregate of the local uptake/activity within the region of interest (i.e. hippocampus) and voxels from other tissue classes (i.e. white matter or surrounding CSF). This issue may be more problematic in cortical analyses because the cortical ribbon has a thickness (generally 2 to 3 mm) that is similar to the typical voxel diameters in PET and fMRI data. Since the partial volume effect (PVE) is proportionate to the amount of atrophy, group differences may be artificially attenuated (amyloid measurements) or inflated (FDG-PET, ASL and fMRI) if atrophy is not accounted for.

CONCLUSIONS

The selective investigation of individuals with increased risks of AD presents an invaluable opportunity to elucidate the presence, magnitude and spatial mapping of functional imaging markers associated with the insidious development of dementia from the presymptomatic state. The evidence reviewed herein strongly suggests that changes as seen on functional imaging are early features of AD. In line with the “amyloid cascade” hypothesis, PET studies have established the presence of amyloid accumulation in FAD and ApoE4 carriers as early as 15 years before ensuing cognitive decline. However, there are still unresolved questions concerning the specificity and the clinical implications of regional amyloid pathology (i.e. striatal regions) as there is insufficient evidence for a close relationship with cognitive impairment. Metabolite abnormalities detected by MRS have also been demonstrated many years before predicted onset of dementia in FAD. Downstream events of the neurodegenerative cascade, such as hypometabolism and decreased CBF, are temporally closer to cognitive decline and may serve as better markers of disease progression. FDG-PET and ASL studies have revealed hypo-metabolism and perfusion within characteristic AD regions, and that these changes may even precede structural atrophy. Other research groups have devised novel experimental paradigms that are designed to challenge

specific cognitive domains. Although there is clear evidence for physiological disruptions in preclinical AD, the *directionality* and *interpretation* of task-evoked fMRI changes are still being contested. That could be also age-dependent nuances in the associations between AD risk factors and functional imaging parameters. For instance, the MTL is associated with an upsurge of functional activity in younger ApoE4 carriers before demonstrating hypoactivation in older carriers as in patients with MCI and AD. Finally, although our previous review in preclinical AD has identified vulnerable foci of structural degeneration (Mak et al., 2016b), the independence and antecedence of functional deficits relative to grey matter atrophy suggests that these techniques may well be more sensitive to disease-related changes in preclinical AD. With more validation efforts in larger samples and longitudinal studies, we anticipate that functional modalities are well-poised to serve as outcome measures in future clinical trials.

ACKNOWLEDGMENTS

This study was supported by the National Institute for Health Research (NIHR, RG64473), Cambridge Biomedical Research Centre and Biomedical Research Unit in Dementia. Elijah Mak was in the receipt of the Gates Cambridge studentship.

REFERENCES

- Bateman, R. J., Xiong, C., Benzinger, T. L. S., Fagan, A. M., Goate, A., Fox, N. C., ... Morris, J. C. (2012). Clinical and biomarker changes in dominantly inherited Alzheimer's disease. *The New England Journal of Medicine*, 367(9), 795–804. <https://doi.org/10.1056/NEJMoa1202753>
- Beckmann, C. (2005). Investigations into resting-state connectivity using independent component analysis. *Philosophical Transactions of the Royal Society*, 360(1457), 1001–1013. <https://doi.org/10.1098/rstb.2005.1634>
- Biswal, B., Yetkin, F. Z., Haughton, V. M., & Hyde, J. S. (1995). Functional connectivity in the motor cortex of resting human brain using echo-planar MRI. *Magnetic Resonance in Medicine*, 34(4), 537–41. Retrieved from <http://www.ncbi.nlm.nih.gov/pubmed/8524021>
- Bloom, G. S. (2014). Amyloid- β and tau: the trigger and the bullet in Alzheimer's disease pathogenesis. *JAMA Neurology*, 71(4), 505. <https://doi.org/10.1001/jamaneurol.2013.5847>
- Braak, H., & Braak, E. (1990). Alzheimer's disease: striatal amyloid deposits and neurofibrillary changes. *Journal of Neuropathology and Experimental Neurology*, 49(3), 215–24. Retrieved from <http://www.ncbi.nlm.nih.gov/pubmed/1692337>
- Braskie, M. N., Medina, L. D., Rodriguez-Agudelo, Y., Geschwind, D. H., Macias-Islas, M. A., Thompson, P. M., ... Ringman, J. M. (2013). Memory performance and fMRI signal in presymptomatic familial Alzheimer's disease. *Human Brain Mapping*, 34(12), 3308–3319. <https://doi.org/10.1002/hbm.22141>
- Buckner, R. L., Snyder, A. Z., Shannon, B. J., LaRossa, G., Sachs, R., Fotenos, A. F., ... Mintun, M. A. (2005). Molecular, Structural, and Functional Characterization of Alzheimer's Disease: Evidence for a Relationship between Default Activity, Amyloid, and Memory. *Journal of Neuroscience*, 25(34).
- Chen, C., Chen, C., Wu, D., Chi, N., Chen, P., Liao, Y., ... Hu, C. (2013). Effects of the apolipoprotein E ϵ 4 allele on functional MRI during n-back working memory tasks in healthy

middle-aged adults. *AJNR. American Journal of Neuroradiology*, 34(6), 1197–202.

<https://doi.org/10.3174/ajnr.A3369>

Chhatwal, J. P., Schultz, A. P., Johnson, K., Benzinger, T. L. S., Jack, C., Ances, B. M., ...

Sperling, R. A. (2013). Impaired default network functional connectivity in autosomal dominant Alzheimer disease. *Neurology*, 81(8), 736–744.

<https://doi.org/10.1212/WNL.0b013e3182a1aafe>

Debette, S., Wolf, P. A., Beiser, A., Au, R., Himali, J. J., Pikula, A., ... Seshadri, S. (2009).

Association of parental dementia with cognitive and brain MRI measures in middle-aged adults. *Neurology*, 73(24), 2071–2078. <https://doi.org/10.1212/WNL.0b013e3181c67833>

Dennis, N. A., Browndyke, J. N., Stokes, J., Need, A., Burke, J. R., Welsh-Bohmer, K. A., &

Cabeza, R. (2010). Temporal lobe functional activity and connectivity in young adult APOE $\epsilon\epsilon$ 4 carriers. *Alzheimer's and Dementia*, 6(4), 303–311.

<https://doi.org/10.1016/j.jalz.2009.07.003>

Dickerson, B. C., Salat, D. H., Greve, D. N., Chua, E. F., Rand-Giovannetti, E., Rentz, D. M., ...

Sperling, R. A. (2005). Increased hippocampal activation in mild cognitive impairment compared to normal aging and AD. *Neurology*, 65(3), 404–11.

<https://doi.org/10.1212/01.wnl.0000171450.97464.49>

Filippini, N., Macintosh, B. J., Hough, M. G., Goodwin, G. M., & Frisoni, G. B. (2009). Distinct patterns of brain activity in young carriers of the APOE- ϵ 4 allele, 106(17), 7209–7214.

Filippini, N., MacIntosh, B. J., Hough, M. G., Goodwin, G. M., Frisoni, G. B., Smith, S. M., ...

Mackay, C. E. (2009). Distinct patterns of brain activity in young carriers of the APOE-epsilon4 allele. *Proceedings of the National Academy of Sciences of the United States of America*, 106(17), 7209–14. <https://doi.org/10.1073/pnas.0811879106>

Fleisher, A. S., Chen, K., Liu, X., Ayutyanont, N., Roontiva, A., Thiyyagura, P., ... Reiman, E. M.

(2013). Apolipoprotein E $\epsilon\epsilon$ 4 and age effects on florbetapir positron emission tomography in

healthy aging and Alzheimer disease. *Neurobiology of Aging*, 34(1), 1–12.

<https://doi.org/10.1016/j.neurobiolaging.2012.04.017>

Fleisher, A. S., Chen, K., Quiroz, Y. T., Jakimovich, L. J., Gomez, M. G., Langois, C. M., ...

Reiman, E. M. (2012). Florbetapir PET analysis of amyloid- β deposition in the presenilin 1 E280A autosomal dominant Alzheimer's disease kindred: A cross-sectional study. *The Lancet Neurology*, 11(12), 1057–1065. [https://doi.org/10.1016/S1474-4422\(12\)70227-2](https://doi.org/10.1016/S1474-4422(12)70227-2)

Fleisher, A. S., Chen, K., Quiroz, Y. T., Jakimovich, L. J., Gutierrez Gomez, M., Langois, C. M., ...

Reiman, E. M. (2015). Associations between biomarkers and age in the presenilin 1 E280A autosomal dominant Alzheimer disease kindred: a cross-sectional study. *JAMA Neurology*, 72(3), 316–24. <https://doi.org/10.1001/jamaneurol.2014.3314>

Fleisher, A. S., Podraza, K. M., Bangen, K. J., Taylor, C., Sherzai, A., Sidhar, K., ... Buxton, R. B.

(2009). Cerebral perfusion and oxygenation differences in Alzheimer's disease risk. *Neurobiology of Aging*, 30(11), 1737–1748.

<https://doi.org/10.1016/j.neurobiolaging.2008.01.012>

Fleisher, A. S., Sherzai, A., Taylor, C., Langbaum, J. B. S., Chen, K., & Buxton, R. B. (2009).

Resting-state BOLD networks versus task-associated functional MRI for distinguishing Alzheimer's disease risk groups. *NeuroImage*, 47(4), 1678–1690.

<https://doi.org/10.1016/j.neuroimage.2009.06.021>

Godbolt, A. K., Waldman, A. D., MacManus, D. G., Schott, J. M., Frost, C., Cipolotti, L., ...

Rossor, M. N. (2006). MRS shows abnormalities before symptoms in familial Alzheimer disease. *Neurology*, 66(5), 718–722. <https://doi.org/10.1212/01.wnl.0000201237.05869.df>

Goveas, J. S., Xie, C., Chen, G., Li, W., Ward, B. D., Franczak, M. B., ... Li, S. J. (2013).

Functional Network Endophenotypes Unravel the Effects of Apolipoprotein E Epsilon 4 in Middle-Aged Adults. *PLoS ONE*, 8(2), 1–10. <https://doi.org/10.1371/journal.pone.0055902>

Graff-Radford, J., Boeve, B. F., Murray, M. E., Ferman, T. J., Tosakulwong, N., Lesnick, T. G., ...

- Kantarci, K. (2014). Regional proton magnetic resonance spectroscopy patterns in dementia with Lewy bodies. *Neurobiology of Aging*, 35(6), 1483–90.
<https://doi.org/10.1016/j.neurobiolaging.2014.01.001>
- Gusnard, D. a, & Raichle, M. E. (2001). Searching for a baseline: functional imaging and the resting human brain. *Nature Reviews. Neuroscience*, 2(10), 685–694.
<https://doi.org/10.1038/35094500>
- Hays, C. C., Zlatar, Z. Z., & Wierenga, C. E. (2016). The Utility of Cerebral Blood Flow as a Biomarker of Preclinical Alzheimer's Disease. *Cellular and Molecular Neurobiology*, 36(2), 167–179. <https://doi.org/10.1007/s10571-015-0261-z>
- Heise, V., Filippini, N., Trachtenberg, A. J., Suri, S., Ebmeier, K. P., & Mackay, C. E. (2014). Apolipoprotein E genotype, gender and age modulate connectivity of the hippocampus in healthy adults. *NeuroImage*, 98, 23–30. <https://doi.org/10.1016/j.neuroimage.2014.04.081>
- Jack, C. R., Knopman, D. S., Jagust, W. J., Petersen, R. C., Weiner, M. W., Aisen, P. S., ... Trojanowski, J. Q. (2013). Tracking pathophysiological processes in Alzheimer's disease: an updated hypothetical model of dynamic biomarkers. *The Lancet Neurology*, 12(2), 207–216.
[https://doi.org/10.1016/S1474-4422\(12\)70291-0](https://doi.org/10.1016/S1474-4422(12)70291-0)
- Kantarci, K. (2013). Proton MRS in mild cognitive impairment. *Journal of Magnetic Resonance Imaging : JMRI*, 37(4), 770–7. <https://doi.org/10.1002/jmri.23800>
- Kantarci, K., Weigand, S. D., Przybelski, S. A., Shiung, M. M., Whitwell, J. L., Negash, S., ... Jr. (2009). Risk of dementia in MCI: combined effect of cerebrovascular disease, volumetric MRI, and 1H MRS. *Neurology*, 72(17), 1519–25. <https://doi.org/10.1212/WNL.0b013e3181a2e864>
- Kennedy, A. M., Frackowiak, R. S. J., Newman, S. K., Bloomfield, P. M., Seaward, J., Roques, P., ... Rossor, M. N. (1995). Deficits in cerebral glucose metabolism demonstrated by positron emission tomography in individuals at risk of familial Alzheimer's disease. *Neuroscience Letters*, 186(1), 17–20. [https://doi.org/10.1016/0304-3940\(95\)11270-7](https://doi.org/10.1016/0304-3940(95)11270-7)

- Klunk, W. E., Engler, H., Nordberg, A., Wang, Y., Blomqvist, G., Holt, D. P., ... Långstro, B. (2004). Imaging Brain Amyloid in Alzheimer ' s Disease with Pittsburgh Compound-B, 306–319. <https://doi.org/10.1002/ana.20009>
- Klunk, W. E., Price, J. C., Mathis, C. A., Tsopelas, N. D., Lopresti, B. J., Ziolk, S. K., ... DeKosky, S. T. (2007). Amyloid deposition begins in the striatum of presenilin-1 mutation carriers from two unrelated pedigrees. *Journal of Neuroscience*, 27(23), 6174–6184. <https://doi.org/10.1523/JNEUROSCI.0730-07.2007>
- Knight, W. D., Okello, A. A., Ryan, N. S., Turkheimer, F. E., Rodriguez Martinez De Llano, S., Edison, P., ... Rossor, M. N. (2011). Carbon-11-Pittsburgh compound B positron emission tomography imaging of amyloid deposition in presenilin 1 mutation carriers. *Brain*, 134(1), 293–300. <https://doi.org/10.1093/brain/awq310>
- Logothetis, N. (2008). What we can do and what we cannot do with fMRI. *Nature*, 453(7197), 869–78. <https://doi.org/10.1038/nature06976>
- Londono, A. C., Castellanos, F. X., Arbelaez, A., Ruiz, A., Aguirre-Acevedo, D. C., Richardson, A. M., ... Lopera, F. (2014). An 1H-MRS framework predicts the onset of Alzheimer's disease symptoms in PSEN1 mutation carriers. *Alzheimer's & Dementia : The Journal of the Alzheimer's Association*, 10(5), 552–561. <https://doi.org/10.1016/j.jalz.2013.08.282>
- Lopera, F., Ardilla, A., Martínez, A., Madrigal, L., Arango-Viana, J. C., Lemere, C. A., ... Kosik, K. S. (1997). Clinical features of early-onset Alzheimer disease in a large kindred with an E280A presenilin-1 mutation. *JAMA*, 277(10), 793–9. Retrieved from <http://www.ncbi.nlm.nih.gov/pubmed/9052708>
- Lustig, C., Snyder, A. Z., Bhakta, M., O'Brien, K. C., McAvoy, M., Raichle, M. E., ... Buckner, R. L. (2003). Functional deactivations: change with age and dementia of the Alzheimer type. *Proc Natl Acad Sci U S A*, 100(24), 14504–14509. <https://doi.org/10.1073/pnas.2235925100> [pii]

- Mak, E., Gabel, S., Mirette, H., Su, L., Williams, G. B., Waldman, A., ... O'Brien, J. (2016a). Structural neuroimaging in preclinical dementia: from microstructural deficits and grey matter atrophy to macroscale connectomic changes. *Ageing Research Reviews*, (October). <https://doi.org/10.1016/j.arr.2016.10.001>
- Mak, E., Gabel, S., Mirette, H., Su, L., Williams, G. B., Waldman, A., ... O'Brien, J. (2016b). Structural neuroimaging in preclinical dementia: from microstructural deficits and grey matter atrophy to macroscale connectomic changes. *Ageing Research Reviews*, 1–15. <https://doi.org/10.1016/j.arr.2016.10.001>
- Mielke, M. M., Wiste, H. J., Weigand, S. D., Knopman, D. S., Lowe, V. J., Roberts, R. O., ... Jr. (2012). Indicators of amyloid burden in a population-based study of cognitively normal elderly. *Neurology*, 79(15), 1570–7. <https://doi.org/10.1212/WNL.0b013e31826e2696>
- Minoshima, S., Frey, K. a, Koeppe, R. a, Foster, N. L., & Kuhl, D. E. (1995). A diagnostic approach in Alzheimer's disease using three-dimensional stereotactic surface projections of fluorine-18-FDG PET. *Journal of Nuclear Medicine : Official Publication, Society of Nuclear Medicine*, 36(7), 1238–1248.
- Minoshima, S., Giordani, B., Berent, S., Frey, K. A., Foster, N. L., & Kuhl, D. E. (1997). Metabolic reduction in the posterior cingulate cortex in very early Alzheimer's disease. *Annals of Neurology*, 42(1), 85–94. <https://doi.org/10.1002/ana.410420114>
- Mondadori, C. R. A., Buchmann, A., Mustovic, H., Schmidt, C. F., Boesiger, P., Nitsch, R. M., ... Henke, K. (2006). Enhanced brain activity may precede the diagnosis of Alzheimer's disease by 30 years. *Brain*, 129(11), 2908–2922. <https://doi.org/10.1093/brain/awl266>
- Morris, J. C., Roe, C. M., Xiong, C., Fagan, A. M., Goate, A. M., Holtzman, D. M., & Mintun, M. A. (2010). APOE predicts amyloid-beta but not tau Alzheimer pathology in cognitively normal aging. *Annals of Neurology*, 67(1), 122–131. <https://doi.org/10.1002/ana.21843>
- Mosconi, L., Mistur, R., Switalski, R., Brys, M., Glodzik, L., Rich, K., ... de Leon, M. J. (2009).

- Declining brain glucose metabolism in normal individuals with a maternal history of Alzheimer disease. *Neurology*, 72(6), 513–20. <https://doi.org/10.1212/01.wnl.0000333247.51383.43>
- Mosconi, L., Sorbi, S., de Leon, M. J., Li, Y., Nacmias, B., Myoung, P. S., ... Pupi, A. (2006). Hypometabolism exceeds atrophy in presymptomatic early-onset familial Alzheimer's disease. *Journal of Nuclear Medicine : Official Publication, Society of Nuclear Medicine*, 47(11), 1778–1786. <https://doi.org/47/11/1778> [pii]
- Musiek, E. S., Chen, Y., Korczykowski, M., Saboury, B., Martinez, P. M., Reddin, J. S., ... Detre, J. A. (2012). Direct comparison of fluorodeoxyglucose positron emission tomography and arterial spin labeling magnetic resonance imaging in Alzheimer's disease. *Alzheimer's & Dementia : The Journal of the Alzheimer's Association*, 8(1), 51–9. <https://doi.org/10.1016/j.jalz.2011.06.003>
- Nichols, L. M., Masdeu, J. C., Mattay, V. S., Kohn, P., Emery, M., Sambataro, F., ... Berman, K. F. (2012). Interactive effect of apolipoprotein e genotype and age on hippocampal activation during memory processing in healthy adults. *Archives of General Psychiatry*, 69(8), 804–813. <https://doi.org/10.1001/archgenpsychiatry.2011.1893>
- O'Brien, J. T., & Herholz, K. (2015). Amyloid imaging for dementia in clinical practice. *BMC Medicine*, 13(1), 163. <https://doi.org/10.1186/s12916-015-0404-6>
- Okonkwo, O. C., Xu, G., Dowling, N. M., Bendlin, B. B., Larue, a, Hermann, B. P., ... Johnson, S. C. (2012). Family history of Alzheimer disease predicts hippocampal atrophy in healthy middle-aged adults. *Neurology*, 78(22), 1769–76. <https://doi.org/10.1212/WNL.0b013e3182583047>
- Patel, K. T., Stevens, M. C., Godfrey, D., Winkler, A. M., Hawkins, K. A., Skudlarski, P., & Bauer, L. O. (2013). Default mode network activity and white matter integrity in healthy middle-aged ApoE4 carriers, 60–67. <https://doi.org/10.1007/s11682-012-9187-y>
- Quiroz, Y. T., Budson, A. E., Celone, K., Ruiz, A., Newmark, R., Castrillón, G., ... Stern, C. E.

- (2010). Hippocampal hyperactivation in presymptomatic familial Alzheimer's disease. *Annals of Neurology*, 68(6), 865–875. <https://doi.org/10.1002/ana.22105>
- Quiroz, Y. T., Schultz, A. P., Chen, K., Protas, H. D., Brickhouse, M., Fleisher, A. S., ... Reiman, E. M. (2015). Brain Imaging and Blood Biomarker Abnormalities in Children With Autosomal Dominant Alzheimer Disease: A Cross-Sectional Study. *JAMA Neurology*, 2114(8), 1–8. <https://doi.org/10.1001/jamaneurol.2015.1099>
- Rabinovici, G. D., & Jagust, W. J. (2009). Amyloid imaging in aging and dementia: Testing the amyloid hypothesis in vivo. *Behavioural Neurology*, 21(1–2), 117–128. <https://doi.org/10.3233/BEN-2009-0232>
- Raichle, M. E., MacLeod, A. M., Snyder, A. Z., Powers, W. J., Gusnard, D. A., & Shulman, G. L. (2001). A default mode of brain function. *Proceedings of the National Academy of Sciences of the United States of America*, 98(2), 676–82. <https://doi.org/10.1073/pnas.98.2.676>
- Reiman, E. M., Caselli, R. J., Chen, K., Alexander, G. E., Bandy, D., & Frost, J. (2001). Declining brain activity in cognitively normal apolipoprotein E epsilon 4 heterozygotes: A foundation for using positron emission tomography to efficiently test treatments to prevent Alzheimer's disease. *Proceedings of the National Academy of Sciences of the United States of America*, 98(6), 3334–9. <https://doi.org/10.1073/pnas.061509598>
- Reiman, E. M., Caselli, R. J., Yun, L. S., Chen, K. W., Bandy, D., Minoshima, S., ... Osborne, D. (1996). Preclinical Evidence Of Alzheimers Disease In Persons Homozygous For the ϵ -4 Allele For Apolipoprotein E. *New England Journal of Medicine*, 334(12), 752–758.
- Ringman, J. M., Medina, L. D., Braskie, M., Rodriguez-Agudelo, Y., Geschwind, D. H., Maclasis, M. A., ... Bookheimer, S. (2011). Effects of risk genes on BOLD activation in presymptomatic carriers of familial alzheimer's disease mutations during a novelty encoding task. *Cerebral Cortex*, 21(4), 877–883. <https://doi.org/10.1093/cercor/bhq158>
- Ritchie, C. W., & Ritchie, K. (2012). The PREVENT study: a prospective cohort study to identify

mid-life biomarkers of late-onset Alzheimer's disease. *BMJ Open*, 2(6), 1–6.

<https://doi.org/10.1136/bmjopen-2012-001893>

Ritchie, K., Guilhem, de R., Ritchie, C. W., Alain, B., Vanessa, P., Artero, S., & Marie-Laure, A.

(2014). COGNITO: Computerized Assessment of Information Processing. *Journal of Psychology & Psychotherapy*, 4(2). <https://doi.org/10.4172/2161-0487.1000136>

Rowe, C. C., Ellis, K. A., Rimajova, M., Bourgeat, P., Pike, K. E., Jones, G., ... Villemagne, V. L.

(2010). Amyloid imaging results from the Australian Imaging, Biomarkers and Lifestyle (AIBL) study of aging. *Neurobiology of Aging*, 31(8), 1275–83.

<https://doi.org/10.1016/j.neurobiolaging.2010.04.007>

Schubert, D. (2005). Glucose metabolism and Alzheimer's disease. *Ageing Research Reviews*,

4(2), 240–257. <https://doi.org/10.1016/j.arr.2005.02.003>

Sheline, Y. I., Morris, J. C., Snyder, A. Z., Price, J. L., Yan, Z., D'Angelo, G., ... Mintun, M. A.

(2010). APOE4 allele disrupts resting state fMRI connectivity in the absence of amyloid plaques or decreased CSF A β 42. *J Neurosci*, 30(50), 17035–17040.

<https://doi.org/10.1523/JNEUROSCI.3987-10.2010>

Sheline, Y. I., & Raichle, M. E. (2013). Resting state functional connectivity in preclinical

Alzheimer's disease. *Biological Psychiatry*, 74(5), 340–347.

<https://doi.org/10.1016/j.biopsych.2012.11.028>

Smith, C. D., Andersen, A. H., Kryscio, R. J., Schmitt, F. A., Kindy, M. S., Blonder, L. X., & Avison,

M. J. (1999). Altered brain activation in cognitively intact individuals at high risk for

Alzheimer's disease. *Neurology*, 53(7), 1391–1391. <https://doi.org/10.1212/WNL.53.7.1391>

Su, Y., Liang, X., Schoepf, U., Varga-Szemes, A., West, H., Qi, R., ... Jiang MD, P. (2015). APOE

Polymorphism Affects Brain Default Mode Network in Healthy Young Adults: A STROBE

Article. *Medicine (Baltimore)*, 94(52), e1734. <https://doi.org/10.1097/MD.0000000000001734>

Thal, D. R., Rüb, U., Orantes, M., & Braak, H. (2002). Phases of A beta-deposition in the human

brain and its relevance for the development of AD. *Neurology*, 58(12), 1791–800. Retrieved from <http://www.ncbi.nlm.nih.gov/pubmed/12084879>

- Trivedi, M. a, Schmitz, T. W., Ries, M. L., Torgerson, B. M., Sager, M. a, Hermann, B. P., ... Johnson, S. C. (2006). Reduced hippocampal activation during episodic encoding in middle-aged individuals at genetic risk of Alzheimer's disease: a cross-sectional study. *BMC Medicine*, 4, 1. <https://doi.org/10.1186/1741-7015-4-1>
- Van Steenoven, I., Aarsland, D., Weintraub, D., Londos, E., Blanc, F., Van Der Flier, W. M., ... Lemstra, A. W. (2016). Cerebrospinal fluid Alzheimer's disease biomarkers across the spectrum of lewy body diseases: Results from a large multicenter cohort. *Journal of Alzheimer's Disease*, 54(1), 287–295. <https://doi.org/10.3233/JAD-160322>
- Villemagne, V. L., Ataka, S., Mizuno, T., Brooks, W. S., Wada, Y., Kondo, M., ... Rowe, C. C. (2009). High striatal amyloid beta-peptide deposition across different autosomal Alzheimer disease mutation types. *Archives of Neurology*, 66(12), 1537–44. <https://doi.org/10.1001/archneurol.2009.285>
- Villemagne, V. L., Mulligan, R. S., Pejoska, S., Ong, K., Jones, G., O'Keefe, G., ... Rowe, C. C. (2012). Comparison of 11C-PiB and 18F-florbetaben for A β imaging in ageing and Alzheimer's disease. *European Journal of Nuclear Medicine and Molecular Imaging*, 39(6), 983–989. <https://doi.org/10.1007/s00259-012-2088-x>
- Wierenga, C. E., & Bondi, M. W. (2007). Use of functional magnetic resonance imaging in the early identification of Alzheimer's disease. *Neuropsychology Review*, 17(2), 127–143. <https://doi.org/10.1007/s11065-007-9025-y>
- Wierenga, C. E., Clark, L. R., Dev, S. I., Shin, D. D., Jurick, S. M., Rissman, R. A., ... Bondi, M. W. (2013). Interaction of age and APOE genotype on cerebral blood flow at rest. *Journal of Alzheimer's Disease*, 34(4), 921–935. <https://doi.org/10.3233/JAD-121897>
- Xiong, C., Roe, C. M., Buckles, V., Fagan, a., Holtzman, D., Balota, D., ... Morris, J. C. (2011).

Role of Family History for Alzheimer Biomarker Abnormalities in the Adult Children Study.

Archives of Neurology, 68(10), 1313–1319. <https://doi.org/10.1001/archneurol.2011.208>

FIGURE AND TABLES

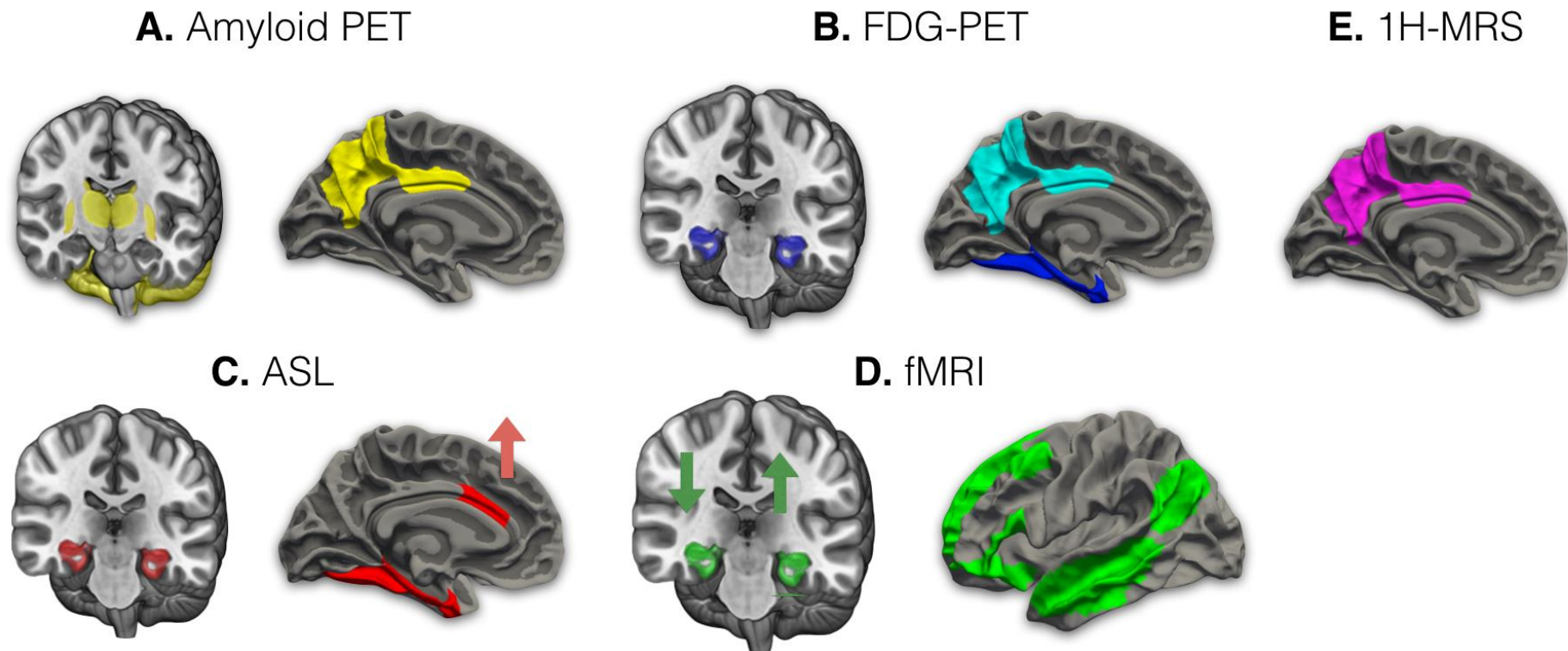


Figure 1. Schematic figure of the principal imaging findings. (A) At-risk individuals exhibit an atypical pattern of amyloid accumulation within the striatal regions, thalamus and the cerebellum. Increased amyloid has also been reported in the precuneus and the posterior cingulate cortex, both of which are early sites of vulnerability in MCI and AD; (B) The MTL is frequently characterized by hypometabolism, whereas others have reported stronger associations between ApoE4 and hypometabolism within the posterior cingulate and precuneus compared to MTL volumes or metabolism; (C) Individuals with ApoE4 and a family history of AD showed decreased perfusion in the MTL that is independent of grey matter atrophy. There is also evidence to imply compensatory hyperfusion

in the anterior cingulate cortex among younger ApoE4 carriers; (D) fMRI task-based studies have consistently demonstrated hypoactivation of the MTL during episodic memory tasks in older ApoE4 subjects (down-ward arrow). However, younger at-risk individuals tend to show hyperactivation (upward arrow). The DMN is frequently associated with functional abnormalities in ApoE4 and FAD mutation carriers. The effect size of rsfMRI differences has been reportedly greater compared to task-based fMRI; (E) ¹H-MRS studies in FAD mutation carriers have reported variations of brain metabolite levels in the posterior cingulate cortex and precuneus. Abbreviations: MCI = Mild cognitive impairment; AD = Alzheimer's disease, FAD = familial Alzheimer's disease; ApoE4 = apolipoprotein epsilon-4 allele; MTL = medial temporal lobe, RS-fMRI = resting-state functional magnetic resonance imaging; DMN = default mode network; ¹H-MRS = magnetic resonance spectroscopy.