

The Genetics of Pneumothorax

Philip M. Boone, MD, PhD,^{1,2} Rachel M. Scott, BA,³ Stefan J. Marciniak, PhD, MB BChir, FRCP, MA,^{3,4} Elizabeth P. Henske, MD,^{5,†} Benjamin A. Raby, MD, MPH^{5,6,†,*}

- 1) Harvard Genetics Training Program, Boston, MA, USA;
- 2) Center for Genomic Medicine, Massachusetts General Hospital, Boston, MA, USA;
- 3) Cambridge Institute for Medical Research, University of Cambridge, Cambridge, UK;
- 4) Division of Respiratory Medicine, Addenbrooke's Hospital, Cambridge, UK;
- 5) Pulmonary Genetics Center, Division of Pulmonary and Critical Care Medicine, Brigham and Women's Hospital, Harvard Medical School, Boston, MA, USA;
- 6) Channing Division of Network Medicine, Department of Medicine, Brigham and Women's Hospital, Boston, MA, USA.

†Equal contribution.

*Correspondence:

Dr. Benjamin Raby
Department of Medicine, Division of Pulmonary and Critical Care Medicine
Brigham and Women's Hospital
Harvard Medical School
181 Longwood Ave, Rm 447
Boston, MA 02115
Tel: +1 (617) 525-2739
Fax: +1 (617) 525-0958
E-mail: rebar@channing.harvard.edu

Key words: Pneumothorax, genetics, familial spontaneous pneumothorax, *FLCN* gene, Birt-Hogg-Dubé syndrome, Marfan syndrome

Abstract

A genetic influence on spontaneous pneumothoraces – those occurring without a traumatic or iatrogenic cause – is supported by several lines of evidence: 1) Pneumothorax can cluster in families (i.e. familial spontaneous pneumothorax); 2) Mutations in the *FLCN* gene have been found in both familial and sporadic cases; and 3) Pneumothorax is a known complication of several genetic syndromes. Herein we review known genetic contributions to both sporadic and familial pneumothorax. We summarize the pneumothorax-associated genetic syndromes, including Birt-Hogg-Dubé syndrome, Marfan syndrome, vascular (type IV) Ehlers-Danlos syndrome, alpha-1-antitrypsin deficiency, tuberous sclerosis complex/lymphangioleiomyomatosis (LAM), Loeys-Dietz syndrome, cystic fibrosis, homocystinuria, and cutis laxa, among others. At times, pneumothorax is their herald manifestation. These syndromes have serious potential extrapulmonary complications (e.g. malignant renal tumors in Birt-Hogg-Dubé syndrome), and surveillance and/or treatment is available for most disorders; thus, establishing a diagnosis is critical. To facilitate this, we provide an algorithm to guide the clinician in discerning which cases of spontaneous pneumothorax may have a genetic or familial contribution, which cases warrant genetic testing, and which cases should prompt an evaluation by a geneticist.

Introduction

Spontaneous pneumothoraces are defined by air in the pleural space arising from neither trauma nor an iatrogenic cause. An anatomic or mechanical cause is identifiable in all cases of secondary spontaneous pneumothorax, which by definition arise from clinically recognizable underlying lung disease (e.g. tuberculosis). Even in primary spontaneous pneumothorax, defined by a lack of overt lung disease, emphysema-like anomalies (blebs, cysts, or bullae) are observed at surgery or on CT in most cases (1). Additional anatomic associations include being taller and thinner than average (2). Smoking is the primary environmental risk factor for primary spontaneous pneumothorax (3).

Several lines of evidence support genetic contributions to pneumothorax. Foremost are familial clustering, observed in 10-12% of cases, and the finding of gene mutations in both familial and sporadic cases. Additionally, pneumothorax is a feature of several Mendelian disorders, for example Birt-Hogg-Dubé and Marfan syndromes.

In this review, we discuss known genetic contributions to both sporadic and familial pneumothorax and summarize the pneumothorax-associated genetic syndromes, all of which have serious potential complications and of which pneumothorax is occasionally the presenting feature. We provide an algorithm to guide the clinician in discerning which cases of spontaneous pneumothorax may have a genetic or familial contribution, and which of these cases should prompt genetic testing and/or evaluation by a geneticist.

Sporadic pneumothorax

Primary spontaneous pneumothoraces occur without a family history in the majority (88-90%) of cases (4, 5). We refer to these non-familial cases as sporadic pneumothorax.

Genetic studies of sporadic pneumothorax cohorts have focused on *FLCN*, the gene for Birt-Hogg-Dubé syndrome (BHDS). The BHDS phenotype includes lung cysts and pneumothorax in addition to renal cancer and skin findings, so investigators hypothesized that some variants in this gene might lead to a lung-only phenotype. No mutations were identified among ten sporadic cases screened by *FLCN* sequencing (6). However, among 92 sporadic pneumothorax patients screened for sequence errors and deletions, five (5%) had *FLCN* mutations (5). *FLCN* promoter methylation changes do not explain *FLCN*-negative sporadic pneumothorax (7).

Several additional studies of spontaneous pneumothorax have been reported that did not adequately enumerate family background. Nonetheless, if one were to assume that the majority of these cases are sporadic (supported by the higher prevalence of sporadic over familial pneumothorax), then these studies of all comers can provide insights regarding the role of genetics in sporadic pneumothorax:

To investigate whether mutations in the genes for additional pneumothorax-associated syndromes explain isolated pneumothorax, Zhang et al. screened for point mutations and deletions in *FBNI*, *COL3A1*, *CBS*, *SERPINA1*, *TSC1* and *TSC2*, and *FLCN* (8). Three of 21 subjects had predicted-pathogenic mutations: two (10%) in *FLCN* and one (5%) in *FBNI*. Three variants of uncertain significance (one in *FBNI*, *TSC1*, and *FLCN*) were also found. While blebs and emphysema-like changes in spontaneous pneumothorax are typically apical (1), BHDS features predominately lower-lobe cysts (9, 10). To investigate whether non-apical lung cysts might herald *FLCN* mutations among patients with spontaneous pneumothorax, Johannesma et al. screened 40 non-familial and familial SP patients with chest CT (11); indeed, all three subjects with cysts below the carina had *FLCN* mutations. To determine whether common genetic variants play a role in

pneumothorax risk, Sousa et al. performed a genome-wide association study of spontaneous pneumothorax (12). No SNPs met the Bonferroni correction threshold in the replication dataset.

Familial pneumothorax

10-12% of patients with spontaneous pneumothorax have a family history, termed familial spontaneous pneumothorax (FSP) (4, 5). The male:female ratio in FSP is 1.7:1 (4), less skewed than for all spontaneous pneumothoraces (2.1-6.2:1) (13-16). The risk of recurrent pneumothorax may be higher in FSP (68-72%) (6, 17) than in sporadic pneumothorax (13-54%) (11-13, 18), although the studies arriving at these recurrence rates differ in methodology, making the comparison imperfect. A higher recurrence rate when a family history is known could argue for surgical intervention after the first pneumothorax (19, 20).

While some FSP families are identifiably autosomal dominant (AD) (Fig. 1a), in others the inheritance pattern is ambiguous (21). Indeed, among 29 FSP pedigrees, all were consistent with AD inheritance with a penetrance of 21% in females and 50% in males, but many of the pedigrees could also follow an X-linked recessive model (Fig. 1b) (4).

Several attempts have been made to map the genetic cause(s) of FSP. In three FSP families, pneumothorax did not segregate with *FBN1*, the disease gene for Marfan syndrome (22). Linkage to the HLA-A2B40 haplotype exists in some families (23, 24) but not others (17, 25). In a large FSP family, CT scans revealed multiple asymptomatic family members with bullae randomly distributed throughout the lungs, transmitted in an AD pattern (Fig. 1c) (26). A heterozygous, predicted-truncating mutation was found in *FLCN*, the disease gene for Birt-Hogg-Dubé syndrome (BHDS). The penetrance of bullae in mutation carriers was 100%; for pneumothorax it was ~40%. The prevalence of *FLCN* mutations in FSP is 17-50% (5, 6).

Thus, a considerable proportion of FSP is attributable to mutations in *FLCN*. The remainder of FSP is likely caused by mutations in one or more yet-undescribed disease genes. By definition, FSP families do not manifest renal or dermatological findings of BHDS. It is unknown what contributes to the full BHDS vs restricted FSP phenotype.

Genetic syndromes predisposing to pneumothorax

Pneumothorax is at times a feature of a multisystem genetic syndrome (Table 1, Figure 2). These can be divided into three mechanistic classes (27): 1) those arising from mutations in tumor suppressor genes; 2) connective tissue disorders; and 3) those in which normal lung architecture is effaced. Given that these syndromes have serious, often-preventable complications, it is essential to make the correct diagnosis when pneumothorax is the presenting manifestation.

Syndromes related to tumor suppressor genes

Birt-Hogg-Dubé syndrome

Birt-Hogg-Dubé syndrome (BHDS) is an autosomal dominant condition caused by heterozygous mutations in *FLCN*, encoding folliculin (28). The full BHDS phenotype includes skin lesions, kidney cancer, lung cysts, and pneumothorax (Fig. 2a-c) (29). Incomplete and age-dependent penetrance of features is characteristic (30). Skin findings include fibrofolliculomas (hamartomas of hair follicles) and trichodiscomas (tumors of the hair disk) (Fig. 2a) (29). These lesions are clinically identical, appearing as small, dome-shaped papules typically on the face, neck, chest, back, and arms. Skin tags are also observed frequently. Renal cancer subtypes include hybrid oncocytic/chromophobe tumors, chromophobe carcinomas, clear cell carcinomas, oncocytomas, and papillary renal cell carcinomas (31); their combined prevalence was estimated

at 6.5% in a review of the literature (29), while a higher rate (~20%) was found in a selected set of NIH cases (30). Screening for renal tumors via imaging is the key intervention for BHDS; however, there is to date no consensus regarding the optimal modality (e.g. MRI, contrast CT, ultrasound) or the timing of imaging (i.e. earliest age, interval between tests), although algorithms have been suggested (29, 32). Although some authors have suggested colorectal cancer as a feature of BHDS (33), it is not an accepted part of the phenotype (29, 32, 34).

The lung cysts of BHDS tend to be basal (below the carina) and subpleural (Fig. 2b-c) (9, 34). They vary in number and size, and most are non-spherical (9). Pulmonary cysts in BHDS have a penetrance of 83-100% (30, 34-37), while they are detected in 10% of unaffected control family members (34). BHDS cysts are usually asymptomatic, and spirometry is typically normal.

The prevalence of pneumothorax in BHDS is 22-41% (30, 34-38). Pneumothoraces in BHDS tend to arise in early- to mid-adulthood (37) but can affect children (39). They can be the presenting sign of BHDS (40). They are often recurrent (40-75%; (35, 37)). Resection or pleurodesis have been suggested after first-time pneumothorax in BHDS (41, 42).

Among BHDS patients, risk factors for pneumothorax include family history of pneumothorax (36), larger cyst size and number (37), extent of lower lung disease (35), flying (42, 43), and scuba diving (43). Curiously, smoking is not a risk factor (32, 37). There is no genotype-phenotype correlation nor modifier gene known to affect pneumothorax risk in BHDS (36).

How *FLCN* mutations lead to cyst formation is unknown. One proposal is based on the observation that folliculin is involved in cell:cell adhesion via the desmosomal protein PKP4/p0071 (44, 45); this suggests that poor stretch tolerance to lung pressure may allow cyst formation (46).

Tuberous sclerosis and pulmonary lymphangioleiomyomatosis (LAM)

Pulmonary lymphangioleiomyomatosis (LAM) is a progressive lung disease involving infiltration of the alveolar septa with smooth muscle-like LAM cells and the development of cysts that compromise normal lung parenchyma (47). LAM is typically diagnosed in young adulthood (48) and affects almost exclusively females – a presumed effect of estrogen (49-52). LAM occurs both sporadically and in association with tuberous sclerosis complex (TSC), an autosomal dominant genetic syndrome caused by germline loss-of-function mutations in *TSC1* (encoding hamartin) or *TSC2* (encoding tuberin) (53, 54). Multitudinous clinical findings are possible in TSC (Table 1; Fig. 2q-y), affecting the brain, skin, abdominal viscera, heart, eyes, mouth, and lung. The lung phenotypes include LAM and micronodular pneumocyte hyperplasia. Among LAM patients, TSC patients (TSC-LAM) make up 15%, while the remaining 85% are sporadic (48). A very small number of men have LAM, all of whom have TSC-LAM (55).

TSC is a syndrome of hamartomas, explained by hamartin's and tuberin's role in regulating cell growth and division via the mTORC1 and other pathways (56). Although women with sporadic LAM lack germline mutations in *TSC1/2*, mosaic inactivating mutations in these genes are found in the pulmonary LAM cells of most patients (57-60). Nearly 30% of sporadic LAM patients have renal angiomyolipomas (48), a feature of TSC, which contain *TSC2* mutations (57). The same *TSC2* mutation is found in the angiomyolipoma and the LAM cells (57). In addition, LAM can recur after lung transplantation, and the recurrent LAM cells carry the original *TSC2* mutation (61). These findings suggest that LAM is a low-grade, metastatic neoplasm (62).

Pneumothorax is the most common presenting sign of LAM (~1/3 of cases) (48). Other presenting features include shortness of breath, wheezing, and abnormal imaging including diffuse reticular pattern on X-ray and diffuse interstitial changes with infiltrates and cysts on CT (48).

Cysts are generally <2 cm, round, and diffuse with no relationship to pleura or vessels, (41). CT reveals cystic changes consistent with LAM in 34-81% of women and 0-10% of men with TSC (63-65). With progression, LAM can cause chest pain, cough, hemoptysis, pleural effusions including chylous effusions, airway obstruction demonstrated via spirometry, and respiratory failure (48). Beyond imaging, the diagnosis of LAM is aided by lung biopsy, lymph node biopsy, and the serum biomarker VEGF-D (66-70).

The lifetime incidence of pneumothorax in LAM is 56-66% (48, 71, 72). Pneumothoraces are recurrent in 73-77% of patients (72, 73), with a mean number of 4.4 +/-0.5 (48). Risk factors for pneumothorax in LAM are prior pneumothorax (72), faster rate of FEV₁ decline (71), and larger cyst size (71). Individuals with a prior pneumothorax had lower VEGF-D levels (74). Chronic loculated pneumothoraces are not worsened by flight, leading to the recommendation to avoid flight only in LAM patients with recent pneumothorax or current symptoms of pneumothorax (75). Pregnancy exacerbates respiratory symptoms in some women with LAM (48) and appears to be a risk factor for pneumothorax (76), however a lack of prospective studies makes the risk difficult to quantify. Polymorphisms in extracellular matrix proteins (collagen, elastin, matrix metalloproteinase-1) were not associated with pneumothorax in one study (71).

The mTORC1 inhibitor sirolimus (Rapamycin) lowers the rate of decline of FEV₁ in women with LAM (77). This intervention is based on the discovery that *TSC2* mutations result in mTORC1 hyperactivation. Treatment with sirolimus is usually continued indefinitely since lung function was proven to decline after discontinuation. The impact of sirolimus on pneumothorax risk is unknown. Other treatments for LAM include oxygen, lung transplantation, and avoiding both smoking and estrogen supplementation (49, 66). Progesterone derivatives have been used

therapeutically (78) but without definitive benefit (48, 79). Pleurodesis is recommended after the first pneumothorax (67, 72) because of the likelihood of recurrence.

Syndromes of disordered connective tissue

Marfan Syndrome

Marfan syndrome is an autosomal dominant condition caused by heterozygous mutations in *FBNI*, encoding fibrillin 1. Marfan syndrome features include tall stature, thin body habitus, long limbs resulting in decreased upper segment to lower segment ratio, arachnodactyly, chest wall deformity, scoliosis, lens dislocation, and dilation/dissection/aneurysm/rupture of the aorta (Fig. 2d-i) (80). Screening and treatment for cardiovascular complications is the primary intervention in the disorder. Pulmonary features of Marfan syndrome can include congenital malformations (e.g. rudimentary middle lobe), cysts, emphysema, and pneumothorax (81). Large total and residual lung volumes may be present (82).

Apical blebs/bullae were found in Marfan syndrome patients at a rate of 8.9% with X-ray and 10% by CT (83). As 0-15% of healthy individuals have emphysema-like lesions including bullae by CT scan (1, 84) and 6% have blebs at surgery (85), it is unclear if these lung lesions are enriched in Marfan syndrome.

Pneumothorax is enriched among Marfan syndrome patients, estimated at 4-11% (83, 86, 87). Pneumothorax is one of the criteria of the Marfan systemic score (80). Among 8 patients, the median number of pneumothoraces was 1 (range 1-3) (83). Blebs or bullae are a risk factor for pneumothorax; pectus excavatum and smoking are not (83). Despite some familial clustering (88, 89), no genotype-phenotype correlation for pneumothorax is known (83).

At times, pneumothorax is the presenting feature of Marfan syndrome (90). Among 10 sporadic pneumothorax patients screened for the syndrome via hand x-rays (for arachnodactyly) and clinical exam, four had “possible” Marfan syndrome and one had “full-fledged” disease (91). One of 21 (5%) sporadic pneumothorax patients had a stop-gain mutation in *FBNI* (8).

In the lung, fibrillin-containing microfibrils associate with elastin to help form elastic fibers. In a Marfan syndrome mouse model, age-dependent alveolar destruction occurs and appears to involve aberrant TGF- β signaling (92, 93). It is unclear in patients whether skeletal shape, lack of fibrillin, altered elastin, altered TGF- β signaling, or a combination leads to blebs/bullae and/or pneumothorax.

Vascular Ehlers-Danlos syndrome

Ehlers-Danlos syndrome (EDS) is a family of connective disorders mostly resulting from mutant collagens or related proteins (94). Of these subtypes, pneumothorax is a feature only of vascular EDS (type IV; vEDS).

vEDS is autosomal dominant, caused by heterozygous mutations in *COL3A1*, encoding the sole subunit of the homotrimeric type III collagen (95). vEDS can have fatal complications including rupture of arteries, the uterus, and intestines (96). Arterial rupture may be preceded by aneurysms or dissection (96). Other features include thin, translucent skin (Fig. 2j), characteristic facial features, easy bruising, clubfoot, congenital hip dislocation, lax small joints, carotid-cavernous sinus fistula, and pulmonary features (96). Screening and prevention includes periodic imaging of the heart and vessels, blood pressure control, counseling regarding the risks of uterine rupture in pregnancy, and avoidance of colonoscopy and elective invasive arteriography (97).

Pulmonary complications of vEDS include cavitory lesions, cysts, bullae, fibrous nodules, pneumothorax, hemo-pneumothorax, and pulmonary hemorrhage (98, 99). Type III collagen in the lung is expressed in vessels and parenchymal fibroblasts (100). Thus, pulmonary complications of vEDS are proposed to result from poor tissue integrity (101, 102). The fibrous nodules, or fibrous pseudotumors, feature osseous metaplasia and may result from inefficient repair after injury to the pulmonary vessels or interstitium, with type I collagen favored over the absent type III collagen (99, 103-105).

Pneumothorax (99, 106, 107) or hemopneumothorax (108) can be the presenting symptom of vEDS. The penetrance of either pneumothorax or hemothorax in vEDS was 16% in a series diagnosed clinically (97); of individuals diagnosed molecularly, pneumothorax prevalence was 80% (109). There is no known genotype-phenotype correlation for vEDS. Standard treatment of pneumothorax has worked (98).

Loeys-Dietz syndrome

Loeys-Dietz syndrome is an autosomal dominant genetic disorder caused by mutations in *TGFBR2*, *TGFBRI*, *SMAD3*, *TGFB2*, and *TGFB3*. *SMAD2* is a provisional gene. These genes encode components of the TFG- β signaling pathway. Pneumothorax is an occasional feature of Loeys-Dietz syndrome (110). It has been described once as the presenting feature (111). Other features are vascular (arterial aneurysms, dissections, and tortuosity), skeletal (pectus excavatum or carinatum, joint laxity or contractures, cervical spine instability, scoliosis, arachnodactyly, club foot), craniofacial (bifid uvula [Fig. 2k] or cleft palate, hypertelorism, craniosynostosis), cutaneous (translucent skin, dystrophic scars, easy bruising), and uterine (rupture during pregnancy) (112). Vascular features lead to premature death (112).

Homocystinuria

Homocystinuria is an autosomal recessive metabolic disorder caused by biallelic mutations in *CBS*, which encodes cystathionine β -synthase (113). Features are skeletal (tall stature with long limbs, scoliosis, pectus excavatum), ocular (lens dislocation, myopia), vascular (blood clots), CNS (intellectual disability, seizures), and cutaneous (hypopigmentation, livedo reticularis, malar flush) (Fig. 2o-p) (113). Plasma homocysteine and methionine are markedly elevated, and the condition can be diagnosed via elevated methionine on the newborn screen. (113) Therapy exists in the form of a methionine-restricted diet, supplementation with folate, B₁₂, B₆ (if responsive), betaine, and in certain circumstances anti-coagulation (113). Pneumothorax has been reported (114); the incidence is unknown. It has once been the presenting feature (115).

Cutis laxa

Cutis laxa describes loose, redundant, hypoelastic skin particularly over the neck, hands, groin, face, and trunk (Fig. 2n). It is a feature of at least 10 genetic syndromes (116). Several of the cutis laxa syndromes display early-onset emphysema, including autosomal dominant cutis laxa (*ELN* gene), autosomal recessive cutis laxa Ia/Ib (*FBLN4/FBLN5* genes), and Urban-Rifkin-Davis syndrome (*LTBP4* gene). Pneumothorax has been reported occasionally in patients with cutis laxa syndromes (117), more frequently among the subtypes that feature emphysema (118, 119). The incidence of pneumothorax is unknown, and pneumothorax has never been reported as the presenting symptom of a cutis laxa syndrome.

Syndromes that efface normal lung architecture

Alpha-1-antitrypsin deficiency

Alpha-1-antitrypsin deficiency (A1AT deficiency) is an autosomal recessive disease caused by mutations in *SERPINA1* (120). Its protein product, alpha-1 antitrypsin, inhibits the protease neutrophil elastase in the lungs. Individuals with bi-allelic mutations that in combination reduce the circulating levels or activity of A1AT to below ~35% of normal can have early-onset chronic obstructive pulmonary disease (Fig. 2l) (120). The typical pathology is a progressive, panacinar, predominantly lower-lobe emphysema presenting in early to mid-adulthood (121). Other lung findings can include chronic bronchitis and bronchiectasis (122), apical bullae (123), and pneumothorax.

Extrapulmonary complications include neonatal cholestatic jaundice, cirrhosis, and risk of hepatocellular carcinoma, resulting from polymerization of certain mutant forms of A1AT in the endoplasmic reticulum of hepatocytes (124). Panniculitis – painful inflammatory skin nodules/weeping lesions (Fig. 2m) – and vasculitis have also been reported (120).

The incidence of pneumothorax in A1AT deficiency is unknown (125, 126), however of patients homozygous for the most common mutant allele, Pi*Z, 2-3% die of pneumothorax (126, 127). Because pneumothorax can occasionally be the presenting symptom of A1AT deficiency (128, 129), several authors have screened for A1AT deficiency among patients with spontaneous pneumothorax. Estimates of A1AT range from 0 to 8% (1, 130-133). Although smoking is an important risk factor for lung disease progression (134) and death (127) in A1AT deficiency, its effect on pneumothorax risk is unknown. Also unknown is whether genotype or augmentation therapy (infusions of A1AT) can impact pneumothorax incidence or recurrence.

Cystic fibrosis

Cystic fibrosis (CF) is caused by biallelic mutations in *CFTR*. Complications are gastrointestinal (meconium ileus, malabsorption, failure to thrive, pancreatic insufficiency and pancreatitis), reproductive (male infertility), and respiratory. Lung findings derive from thickened mucus affecting the mucociliary elevator and include recurrent infections, inflammation, bronchiectasis, cysts/cavitations, air trapping, hemoptysis, and pneumothorax (135). Pneumothorax as a herald sign of CF is probably rare because: 1) it is a late feature of the disease (136); and 2) CF is screened for in newborns in countries where it is prevalent, so the diagnosis is often made at birth.

Incidence of pneumothorax among CF patients was 2% in children over a 15-year interval (137) and 3% in all ages over a 10-year period (136). Lifetime prevalence was estimated at 8% during the 1950s-80s (138). Specific risk factors for pneumothorax in CF include: older age; FEV₁ <30% predicted; infection with *P. aeruginosa*, *B. cepacia*, or *Aspergillus*; allergic bronchopulmonary aspergillosis; massive hemoptysis; enteral feeding; and pancreatic insufficiency (136). Recurrence is 50-90% ipsilaterally and 46% contralaterally (136, 139). A pneumothorax carries an attributable mortality of 6-14% (140).

Mechanically, pneumothorax risk in CF may derive from effacement of normal lung structures, altered airflow dynamics, air trapping, use of inhaled medications, or noninvasive positive pressure ventilation (135). Risk does not correlate well with blebs or cysts (141). Among 21 CF *carriers*, one had pneumothorax and others had respiratory symptoms including nasal polyps causing obstruction (142), however a larger study showed no difference in pneumothorax, sinusitis, or other respiratory conditions (143).

Management of pneumothorax in CF is debated. Some suggest early surgical intervention (144, 145); others urge caution given potential future lung transplantation (146, 147).

Others

There are reports of pneumothorax in other genetic syndromes. These include: Sotos syndrome (148), spinocerebellar ataxia type 1 (149), telomerase reverse transcriptase (*TERT* gene) mutations (emphysema and pneumothorax in smokers) (150), hereditary mucoepithelial dysplasia (151), and diffuse dendriform pulmonary ossification (152).

A genetic approach to patients with spontaneous pneumothorax

Current clinical guidelines for the evaluation and management of pneumothorax do not address the familial, syndromic, or potentially syndromic cases (153, 154). We argue that establishing a genetic diagnosis is beneficial for patients and their relatives. For the index case, establishing a genetic etiology can guide pneumothorax management, including the need for pleurodesis after first pneumothorax. Moreover, given that the genetic forms of pneumothorax are associated with extra-pulmonary complications, a genetic diagnosis enables targeted surveillance and prophylaxis. Examples include blood pressure control and echocardiography in Marfan syndrome and surveillance for renal tumors in BHDS. The potential benefits to family – whether pneumothorax has occurred in other family members or not – are no less significant. Identification of a pathogenic genetic variant in the index case enables testing, counseling, and surveillance/prophylaxis in family members carrying the same variant. For these reasons, we recommend that an underlying genetic diagnosis be routinely entertained in patients with spontaneous pneumothorax.

Figure 3 provides a basic algorithm to evaluate this question, emphasizing the importance of a focused family history, targeted history taking and physical examination, and careful review

of imaging. Figure 4 provides a graphical representation of which findings are associated with which syndromes.

In addition to pneumothorax, the family history should ascertain associated lung diseases (particularly emphysema, bronchiectasis, and CF), abnormal chest imaging (cysts/blebs/bullae), renal tumors (observed in BHDS and TSC), physical features consistent with pneumothorax-associated syndromes (see Table 1), and consanguinity (which could heighten suspicion for an autosomal recessive condition). While a positive family history can help flag patients, an absent family history should not dissuade pursuit of a genetic cause of pneumothorax; both FSP caused by *FLCN* mutations and dominant pneumothorax-associated syndromes can arise via *de novo* mutations (155) or display reduced penetrance, and autosomal recessive conditions frequently lack family history.

History taking and physical examination should include focused screening for features of pneumothorax-associated genetic syndromes (Table 1). A thorough examination of the skin is essential, as dermatologic manifestations of BHDS are often subtle. Skeletal anomalies, hyperextensibility, and distinct facial features could suggest a connective tissue disorder.

Current clinical guidelines do not recommend chest CT in first-time, unilateral spontaneous pneumothorax (153, 154). However, a recent study demonstrating the cost-effectiveness of CT to detect diffuse, cystic lung diseases in patients with first-time pneumothorax (156) is among the reasons some authors argue for the adoption of this practice (157). While acknowledging that the risk-benefit profile is unknown (11), we suggest considering chest CT in first-time pneumothorax if a family history is present or if the patient is female given that the mutational burden to cause pneumothorax in women appears to be higher (unpublished data) and because of the possibility of LAM. The presence of multiple (158) and/or non-apical cysts (11) may suggest BHDS or *FLCN*-

related FSP. Parenchymal lung disease might suggest A1AT deficiency or LAM, and airways disease CF. Aortic pathology might suggest Marfan syndrome or Loeys-Dietz syndrome.

We recommend genetic testing or evaluation in the following scenarios: An isolated family history of pneumothorax should prompt sequencing and deletion/duplication screening of *FLCN*. This will be positive in 17-50% of cases (5, 6). A family history of blebs/cysts/or bullae or a personal history of non-apical blebs/cysts/bullae should also prompt testing of *FLCN*. In the absence of positive family history and CT data, the merits of *FLCN* testing are not clear, although 10% of these patients will have pathogenic mutations as well. Should the personal or family medical history or the physical examination raise suspicion for a genetic syndrome, we recommend referral to a medical geneticist for a more detailed examination and consideration of genetic testing for pneumothorax-associated syndromes.

Summary

A genetic cause of pneumothorax can have high impact clinical implications. The generalist, emergency physician, radiologist, pulmonologist, surgeon, or other specialist, armed with the above recommendation, is enabled to raise the possibility of a genetic/familial diagnosis in pneumothorax patients. Additional studies – ideally prospective – that test the value of chest CT, genetic testing, and genetics referral to uncover genetic causes of pneumothorax, and the appropriateness of surgery after first-time pneumothorax, will enable the official “society” guidelines to be updated. Furthermore, yet-undiscovered genetic contributions to pneumothorax likely exist, which researchers will uncover in time via assembly and study of patient cohorts and by other methods.

Supplemental Material

None.

Acknowledgements

EH is supported by grants from the NHLBI (U01HL131022-02), the NIDDK (R01DK102146-03), the US Department of Defense Tuberous Sclerosis Medical Research Program, and the Engles Program in TSC and LAM Research. BR is supported by grants from the NHLBI (R01HL118455-04, R01HL123546-03, R01HL130974-02, P01HL132825-02) and the Brigham and Women's Precision Medicine Initiative.

Disclosure Declaration

The authors have no potential conflicts of interest to disclose.

References

1. Bense L, Lewander R, Eklund G, Hedenstierna G, Wiman LG. Nonsmoking, non-alpha 1-antitrypsin deficiency-induced emphysema in nonsmokers with healed spontaneous pneumothorax, identified by computed tomography of the lungs. *Chest* 1993; 103: 433-438.
2. Withers JN, Fishback ME, Kiehl PV, Hannon JL. Spontaneous Pneumothorax. Suggested Etiology and Comparison of Treatment Methods. *Am J Surg* 1964; 108: 772-776.
3. Bense L, Eklund G, Wiman LG. Smoking and the increased risk of contracting spontaneous pneumothorax. *Chest* 1987; 92: 1009-1012.
4. Abolnik IZ, Lossos IS, Zlotogora J, Brauer R. On the inheritance of primary spontaneous pneumothorax. *Am J Med Genet* 1991; 40: 155-158.
5. Ren HZ, Zhu CC, Yang C, Chen SL, Xie J, Hou YY, Xu ZF, Wang DJ, Mu DK, Ma DH, Wang Y, Ye MH, Ye ZR, Chen BF, Wang CG, Lin J, Qiao D, Yi L. Mutation analysis of the FLCN gene in Chinese patients with sporadic and familial isolated primary spontaneous pneumothorax. *Clin Genet* 2008; 74: 178-183.
6. Graham RB, Nolasco M, Peterlin B, Garcia CK. Nonsense mutations in folliculin presenting as isolated familial spontaneous pneumothorax in adults. *Am J Respir Crit Care Med* 2005; 172: 39-44.
7. Ding Y, Zou W, Zhu C, Min H, Ma D, Chen B, Ye M, Pan Y, Cao L, Wan Y, Zhu Q, Xia H, Zhang W, Feng Y, Gao Q, Yi L. Promoter methylation is not associated with FLCN irregularity in lung cyst lesions of primary spontaneous pneumothorax. *Mol Med Rep* 2015; 12: 7770-7776.

8. Zhang X, Ma D, Zou W, Ding Y, Zhu C, Min H, Zhang B, Wang W, Chen B, Ye M, Cai M, Pan Y, Cao L, Wan Y, Jin Y, Gao Q, Yi L. A rapid NGS strategy for comprehensive molecular diagnosis of Birt-Hogg-Dube syndrome in patients with primary spontaneous pneumothorax. *Respir Res* 2016; 17: 64.
9. Tobino K, Gunji Y, Kurihara M, Kunogi M, Koike K, Tomiyama N, Johkoh T, Kodama Y, Iwakami S, Kikkawa M, Takahashi K, Seyama K. Characteristics of pulmonary cysts in Birt-Hogg-Dube syndrome: thin-section CT findings of the chest in 12 patients. *Eur J Radiol* 2011; 77: 403-409.
10. Agarwal PP, Gross BH, Holloway BJ, Seely J, Stark P, Kazerooni EA. Thoracic CT findings in Birt-Hogg-Dube syndrome. *AJR Am J Roentgenol* 2011; 196: 349-352.
11. Johannesma PC, Reinhard R, Kon Y, Sriram JD, Smit HJ, van Moorselaar RJ, Menko FH, Postmus PE. Prevalence of Birt-Hogg-Dube syndrome in patients with apparently primary spontaneous pneumothorax. *Eur Respir J* 2015; 45: 1191-1194.
12. Sousa I, Abrantes P, Francisco V, Teixeira G, Monteiro M, Neves J, Norte A, Robalo Cordeiro C, Moura ESJ, Reis E, Santos P, Oliveira M, Sousa S, Fradinho M, Malheiro F, Negro L, Feijo S, Oliveira SA. Multicentric Genome-Wide Association Study for Primary Spontaneous Pneumothorax. *PLoS One* 2016; 11: e0156103.
13. Sadikot RT, Greene T, Meadows K, Arnold AG. Recurrence of primary spontaneous pneumothorax. *Thorax* 1997; 52: 805-809.
14. Melton LJ, 3rd, Hepper NG, Offord KP. Incidence of spontaneous pneumothorax in Olmsted County, Minnesota: 1950 to 1974. *Am Rev Respir Dis* 1979; 120: 1379-1382.
15. Nakamura H, Konishiike J, Sugamura A, Takeno Y. Epidemiology of spontaneous pneumothorax in women. *Chest* 1986; 89: 378-382.

16. Gupta D, Hansell A, Nichols T, Duong T, Ayres JG, Strachan D. Epidemiology of pneumothorax in England. *Thorax* 2000; 55: 666-671.
17. Lenler-Petersen P, Grunnet N, Jespersen TW, Jaeger P. Familial spontaneous pneumothorax. *Eur Respir J* 1990; 3: 342-345.
18. Guo Y, Xie C, Rodriguez RM, Light RW. Factors related to recurrence of spontaneous pneumothorax. *Respirology* 2005; 10: 378-384.
19. Mikroulis D, Lukman AL, Didilis V, Bougioukas G. Familial spontaneous pneumothorax. *Respirology* 2005; 10: 403.
20. Nickoladze GD. Surgical management of familial spontaneous pneumothorax. *Respir Med* 1990; 84: 107-109.
21. Wilson WG, Aylsworth AS. Familial spontaneous pneumothorax. *Pediatrics* 1979; 64: 172-175.
22. Cardy CM, Maskell NA, Handford PA, Arnold AG, Davies RJ, Morrison PJ, Thornley PE. Familial spontaneous pneumothorax and FBN1 mutations. *Am J Respir Crit Care Med* 2004; 169: 1260-1262.
23. Yamada A, Takeda Y, Hayashi S, Shimizu K. Familial spontaneous pneumothorax in three generations and its HLA. *Jpn J Thorac Cardiovasc Surg* 2003; 51: 456-458.
24. Sharpe IK, Ahmad M, Braun W. Familial spontaneous pneumothorax and HLA antigens. *Chest* 1980; 78: 264-268.
25. Cheng YJ, Chou SH, Kao EL. Familial spontaneous pneumothorax-report of seven cases in two families. *Gaoxiong Yi Xue Ke Xue Za Zhi* 1992; 8: 390-394.

26. Painter JN, Tapanainen H, Somer M, Tukiainen P, Aittomaki K. A 4-bp deletion in the Birt-Hogg-Dube gene (FLCN) causes dominantly inherited spontaneous pneumothorax. *Am J Hum Genet* 2005; 76: 522-527.
27. Scott RM, Henske EP, Raby B, Boone PM, Rusk RA, Marciniak SJ. Familial pneumothorax: towards precision medicine. *Thorax* 2018; 73: 270-276.
28. Nickerson ML, Warren MB, Toro JR, Matrosova V, Glenn G, Turner ML, Duray P, Merino M, Choyke P, Pavlovich CP, Sharma N, Walther M, Munroe D, Hill R, Maher E, Greenberg C, Lerman MI, Linehan WM, Zbar B, Schmidt LS. Mutations in a novel gene lead to kidney tumors, lung wall defects, and benign tumors of the hair follicle in patients with the Birt-Hogg-Dube syndrome. *Cancer Cell* 2002; 2: 157-164.
29. Toro JR. Birt-Hogg-Dube Syndrome. In: R.A. Pagon MPA, H.H. Ardinger, et al., editor. GeneReviews, 2014/08/07 ed: University of Washington; 1993.
30. Schmidt LS, Nickerson ML, Warren MB, Glenn GM, Toro JR, Merino MJ, Turner ML, Choyke PL, Sharma N, Peterson J, Morrison P, Maher ER, Walther MM, Zbar B, Linehan WM. Germline BHD-mutation spectrum and phenotype analysis of a large cohort of families with Birt-Hogg-Dube syndrome. *Am J Hum Genet* 2005; 76: 1023-1033.
31. Dal Sasso AA, Belem LC, Zanetti G, Souza CA, Escuissato DL, Irion KL, Guimaraes MD, Marchiori E. Birt-Hogg-Dube syndrome. State-of-the-art review with emphasis on pulmonary involvement. *Respir Med* 2015; 109: 289-296.
32. Menko FH, van Steensel MA, Giraud S, Friis-Hansen L, Richard S, Ungari S, Nordenskjold M, Hansen TV, Solly J, Maher ER. Birt-Hogg-Dube syndrome: diagnosis and management. *Lancet Oncol* 2009; 10: 1199-1206.

33. Khoo SK, Giraud S, Kahnoski K, Chen J, Motorna O, Nickolov R, Binet O, Lambert D, Friedel J, Levy R, Ferlicot S, Wolkenstein P, Hammel P, Bergerheim U, Hedblad MA, Bradley M, Teh BT, Nordenskjold M, Richard S. Clinical and genetic studies of Birt-Hogg-Dube syndrome. *J Med Genet* 2002; 39: 906-912.
34. Zbar B, Alvord WG, Glenn G, Turner M, Pavlovich CP, Schmidt L, Walther M, Choyke P, Weirich G, Hewitt SM, Duray P, Gabril F, Greenberg C, Merino MJ, Toro J, Linehan WM. Risk of renal and colonic neoplasms and spontaneous pneumothorax in the Birt-Hogg-Dube syndrome. *Cancer Epidemiol Biomarkers Prev* 2002; 11: 393-400.
35. Skolnik K, Tsai WH, Dornan K, Perrier R, Burrowes PW, Davidson WJ. Birt-Hogg-Dube syndrome: a large single family cohort. *Respir Res* 2016; 17: 22.
36. Toro JR, Wei MH, Glenn GM, Weinreich M, Toure O, Vocke C, Turner M, Choyke P, Merino MJ, Pinto PA, Steinberg SM, Schmidt LS, Linehan WM. BHD mutations, clinical and molecular genetic investigations of Birt-Hogg-Dube syndrome: a new series of 50 families and a review of published reports. *J Med Genet* 2008; 45: 321-331.
37. Toro JR, Pautler SE, Stewart L, Glenn GM, Weinreich M, Toure O, Wei MH, Schmidt LS, Davis L, Zbar B, Choyke P, Steinberg SM, Nguyen DM, Linehan WM. Lung cysts, spontaneous pneumothorax, and genetic associations in 89 families with Birt-Hogg-Dube syndrome. *Am J Respir Crit Care Med* 2007; 175: 1044-1053.
38. Houweling AC, Gijzen LM, Jonker MA, van Doorn MB, Oldenburg RA, van Spaendonck-Zwarts KY, Leter EM, van Os TA, van Grieken NC, Jaspars EH, de Jong MM, Bongers EM, Johannesma PC, Postmus PE, van Moorselaar RJ, van Waesberghe JH, Starink TM, van Steensel MA, Gille JJ, Menko FH. Renal cancer and pneumothorax risk in Birt-Hogg-

- Dube syndrome; an analysis of 115 FLCN mutation carriers from 35 BHD families. *Br J Cancer* 2011; 105: 1912-1919.
39. Johannesma PC, van den Borne BE, Gille JJ, Nagelkerke AF, van Waesberghe JT, Paul MA, van Moorselaar RJ, Menko FH, Postmus PE. Spontaneous pneumothorax as indicator for Birt-Hogg-Dube syndrome in paediatric patients. *BMC Pediatr* 2014; 14: 171.
40. Diamond JM, Kotloff RM. Recurrent spontaneous pneumothorax as the presenting sign of the Birt-Hogg-Dube syndrome. *Ann Intern Med* 2009; 150: 289-290.
41. Gupta N, Seyama K, McCormack FX. Pulmonary manifestations of Birt-Hogg-Dube syndrome. *Fam Cancer* 2013; 12: 387-396.
42. Gupta N, Koprass EJ, Henske EP, James LE, El-Chemaly S, Veeraraghavan S, Drake MG, McCormack FX. Spontaneous Pneumothoraces in Patients with Birt-Hogg-Dube Syndrome. *Ann Am Thorac Soc* 2017; 14: 706-713.
43. Johannesma PC, van de Beek I, van der Wel JW, Paul MA, Houweling AC, Jonker MA, van Waesberghe JH, Reinhard R, Starink TM, van Moorselaar RJ, Menko FH, Postmus PE. Risk of spontaneous pneumothorax due to air travel and diving in patients with Birt-Hogg-Dube syndrome. *Springerplus* 2016; 5: 1506.
44. Medvetz DA, Khabibullin D, Hariharan V, Ongusaha PP, Goncharova EA, Schlechter T, Darling TN, Hofmann I, Krymskaya VP, Liao JK, Huang H, Henske EP. Folliculin, the product of the Birt-Hogg-Dube tumor suppressor gene, interacts with the adherens junction protein p0071 to regulate cell-cell adhesion. *PLoS One* 2012; 7: e47842.
45. Nahorski MS, Seabra L, Straatman-Iwanowska A, Wingenfeld A, Reiman A, Lu X, Klomp JA, Teh BT, Hatzfeld M, Gissen P, Maher ER. Folliculin interacts with p0071 (plakophilin-

- 4) and deficiency is associated with disordered RhoA signalling, epithelial polarization and cytokinesis. *Hum Mol Genet* 2012; 21: 5268-5279.
46. Kennedy JC, Khabibullin D, Henske EP. Mechanisms of pulmonary cyst pathogenesis in Birt-Hogg-Dube syndrome: The stretch hypothesis. *Semin Cell Dev Biol* 2016; 52: 47-52.
47. Henske EP, McCormack FX. Lymphangi leiomyomatosis - a wolf in sheep's clothing. *J Clin Invest* 2012; 122: 3807-3816.
48. Ryu JH, Moss J, Beck GJ, Lee JC, Brown KK, Chapman JT, Finlay GA, Olson EJ, Ruoss SJ, Maurer JR, Raffin TA, Peavy HH, McCarthy K, Taveira-Dasilva A, McCormack FX, Avila NA, Decastro RM, Jacobs SS, Stylianou M, Fanburg BL. The NHLBI lymphangi leiomyomatosis registry: characteristics of 230 patients at enrollment. *Am J Respir Crit Care Med* 2006; 173: 105-111.
49. Shen A, Iseman MD, Waldron JA, King TE. Exacerbation of pulmonary lymphangi leiomyomatosis by exogenous estrogens. *Chest* 1987; 91: 782-785.
50. Yu JJ, Robb VA, Morrison TA, Ariazi EA, Karbowniczek M, Astrinidis A, Wang C, Hernandez-Cuebas L, Seeholzer LF, Nicolas E, Hensley H, Jordan VC, Walker CL, Henske EP. Estrogen promotes the survival and pulmonary metastasis of tuberin-null cells. *Proc Natl Acad Sci U S A* 2009; 106: 2635-2640.
51. Yano S. Exacerbation of pulmonary lymphangi leiomyomatosis by exogenous oestrogen used for infertility treatment. *Thorax* 2002; 57: 1085-1086.
52. Yu J, Henske EP. mTOR activation, lymphangiogenesis, and estrogen-mediated cell survival: the "perfect storm" of pro-metastatic factors in LAM pathogenesis. *Lymphat Res Biol* 2010; 8: 43-49.

53. Costello LC, Hartman TE, Ryu JH. High frequency of pulmonary lymphangioliomyomatosis in women with tuberous sclerosis complex. *Mayo Clin Proc* 2000; 75: 591-594.
54. Henske EP, Jozwiak S, Kingswood JC, Sampson JR, Thiele EA. Tuberous sclerosis complex. *Nat Rev Dis Primers* 2016; 2: 16035.
55. Aubry MC, Myers JL, Ryu JH, Henske EP, Logginidou H, Jalal SM, Tazelaar HD. Pulmonary lymphangioliomyomatosis in a man. *Am J Respir Crit Care Med* 2000; 162: 749-752.
56. Au KS, Williams AT, Gambello MJ, Northrup H. Molecular genetic basis of tuberous sclerosis complex: from bench to bedside. *J Child Neurol* 2004; 19: 699-709.
57. Carsillo T, Astrinidis A, Henske EP. Mutations in the tuberous sclerosis complex gene TSC2 are a cause of sporadic pulmonary lymphangioliomyomatosis. *Proc Natl Acad Sci U S A* 2000; 97: 6085-6090.
58. Badri KR, Gao L, Hyjek E, Schuger N, Schuger L, Qin W, Chekaluk Y, Kwiatkowski DJ, Zhe X. Exonic mutations of TSC2/TSC1 are common but not seen in all sporadic pulmonary lymphangioliomyomatosis. *Am J Respir Crit Care Med* 2013; 187: 663-665.
59. Fujita A, Ando K, Kobayashi E, Mitani K, Okudera K, Nakashima M, Miyatake S, Tsurusaki Y, Saitsu H, Seyama K, Miyake N, Matsumoto N. Detection of low-prevalence somatic TSC2 mutations in sporadic pulmonary lymphangioliomyomatosis tissues by deep sequencing. *Hum Genet* 2016; 135: 61-68.
60. Sato T, Seyama K, Fujii H, Maruyama H, Setoguchi Y, Iwakami S, Fukuchi Y, Hino O. Mutation analysis of the TSC1 and TSC2 genes in Japanese patients with pulmonary lymphangioliomyomatosis. *J Hum Genet* 2002; 47: 20-28.

61. Karbowniczek M, Astrinidis A, Balsara BR, Testa JR, Lium JH, Colby TV, McCormack FX, Henske EP. Recurrent lymphangiomyomatosis after transplantation: genetic analyses reveal a metastatic mechanism. *Am J Respir Crit Care Med* 2003; 167: 976-982.
62. McCormack FX, Travis WD, Colby TV, Henske EP, Moss J. Lymphangioleiomyomatosis: calling it what it is: a low-grade, destructive, metastasizing neoplasm. *Am J Respir Crit Care Med* 2012; 186: 1210-1212.
63. Moss J, Avila NA, Barnes PM, Litzemberger RA, Bechtle J, Brooks PG, Hedin CJ, Hunsberger S, Kristof AS. Prevalence and clinical characteristics of lymphangioleiomyomatosis (LAM) in patients with tuberous sclerosis complex. *Am J Respir Crit Care Med* 2001; 164: 669-671.
64. Muzykewicz DA, Sharma A, Muse V, Numis AL, Rajagopal J, Thiele EA. TSC1 and TSC2 mutations in patients with lymphangioleiomyomatosis and tuberous sclerosis complex. *J Med Genet* 2009; 46: 465-468.
65. Cudzilo CJ, Szczesniak RD, Brody AS, Rattan MS, Krueger DA, Bissler JJ, Franz DN, McCormack FX, Young LR. Lymphangioleiomyomatosis screening in women with tuberous sclerosis. *Chest* 2013; 144: 578-585.
66. Johnson SR, Cordier JF, Lazor R, Cottin V, Costabel U, Harari S, Reynaud-Gaubert M, Boehler A, Brauner M, Popper H, Bonetti F, Kingswood C. European Respiratory Society guidelines for the diagnosis and management of lymphangioleiomyomatosis. *Eur Respir J* 2010; 35: 14-26.
67. Gupta N, Finlay GA, Kotloff RM, Strange C, Wilson KC, Young LR, Taveira-DaSilva AM, Johnson SR, Cottin V, Sahn SA, Ryu JH, Seyama K, Inoue Y, Downey GP, Han MK, Colby TV, Wikenheiser-Brokamp KA, Meyer CA, Smith K, Moss J, McCormack FX.

- Lymphangioleiomyomatosis Diagnosis and Management: High-Resolution Chest Computed Tomography, Transbronchial Lung Biopsy, and Pleural Disease Management. An Official American Thoracic Society/Japanese Respiratory Society Clinical Practice Guideline. *Am J Respir Crit Care Med* 2017; 196: 1337-1348.
68. McCormack FX, Gupta N, Finlay GR, Young LR, Taveira-DaSilva AM, Glasgow CG, Steagall WK, Johnson SR, Sahn SA, Ryu JH, Strange C, Seyama K, Sullivan EJ, Kotloff RM, Downey GP, Chapman JT, Han MK, D'Armiento JM, Inoue Y, Henske EP, Bissler JJ, Colby TV, Kinder BW, Wikenheiser-Brokamp KA, Brown KK, Cordier JF, Meyer C, Cottin V, Brozek JL, Smith K, Wilson KC, Moss J. Official American Thoracic Society/Japanese Respiratory Society Clinical Practice Guidelines: Lymphangioleiomyomatosis Diagnosis and Management. *Am J Respir Crit Care Med* 2016; 194: 748-761.
69. Seyama K, Kumasaka T, Souma S, Sato T, Kurihara M, Mitani K, Tominaga S, Fukuchi Y. Vascular endothelial growth factor-D is increased in serum of patients with lymphangioleiomyomatosis. *Lymphat Res Biol* 2006; 4: 143-152.
70. Young LR, Inoue Y, McCormack FX. Diagnostic potential of serum VEGF-D for lymphangioleiomyomatosis. *N Engl J Med* 2008; 358: 199-200.
71. Steagall WK, Glasgow CG, Hathaway OM, Avila NA, Taveira-Dasilva AM, Rabel A, Stylianou MP, Lin JP, Chen X, Moss J. Genetic and morphologic determinants of pneumothorax in lymphangioleiomyomatosis. *Am J Physiol Lung Cell Mol Physiol* 2007; 293: L800-808.
72. Almoosa KF, McCormack FX, Sahn SA. Pleural disease in lymphangioleiomyomatosis. *Clin Chest Med* 2006; 27: 355-368.

73. Hagaman JT, Schauer DP, McCormack FX, Kinder BW. Screening for lymphangioleiomyomatosis by high-resolution computed tomography in young, nonsmoking women presenting with spontaneous pneumothorax is cost-effective. *Am J Respir Crit Care Med* 2010; 181: 1376-1382.
74. Young L, Lee HS, Inoue Y, Moss J, Singer LG, Strange C, Nakata K, Barker AF, Chapman JT, Brantly ML, Stocks JM, Brown KK, Lynch JP, 3rd, Goldberg HJ, Downey GP, Swigris JJ, Taveira-DaSilva AM, Krischer JP, Trapnell BC, McCormack FX. Serum VEGF-D a concentration as a biomarker of lymphangioleiomyomatosis severity and treatment response: a prospective analysis of the Multicenter International Lymphangioleiomyomatosis Efficacy of Sirolimus (MILES) trial. *Lancet Respir Med* 2013; 1: 445-452.
75. Taveira-DaSilva AM, Burstein D, Hathaway OM, Fontana JR, Gochuico BR, Avila NA, Moss J. Pneumothorax after air travel in lymphangioleiomyomatosis, idiopathic pulmonary fibrosis, and sarcoidosis. *Chest* 2009; 136: 665-670.
76. Cohen MM, Freyer AM, Johnson SR. Pregnancy experiences among women with lymphangioleiomyomatosis. *Respir Med* 2009; 103: 766-772.
77. McCormack FX, Inoue Y, Moss J, Singer LG, Strange C, Nakata K, Barker AF, Chapman JT, Brantly ML, Stocks JM, Brown KK, Lynch JP, 3rd, Goldberg HJ, Young LR, Kinder BW, Downey GP, Sullivan EJ, Colby TV, McKay RT, Cohen MM, Korbee L, Taveira-DaSilva AM, Lee HS, Krischer JP, Trapnell BC. Efficacy and safety of sirolimus in lymphangioleiomyomatosis. *N Engl J Med* 2011; 364: 1595-1606.
78. McCarty KS, Jr., Mossler JA, McLelland R, Sieker HO. Pulmonary lymphangiomyomatosis responsive to progesterone. *N Engl J Med* 1980; 303: 1461-1465.

79. Taveira-DaSilva AM, Stylianou MP, Hedin CJ, Hathaway O, Moss J. Decline in lung function in patients with lymphangioleiomyomatosis treated with or without progesterone. *Chest* 2004; 126: 1867-1874.
80. Dietz H. Marfan Syndrome. GeneReviews, 2017/10/12 ed; 1993.
81. Dwyer EM, Jr., Troncale F. Spontaneous Pneumothorax and Pulmonary Disease in the Marfan Syndrome. Report of Two Cases and Review of the Literature. *Ann Intern Med* 1965; 62: 1285-1292.
82. Giske L, Stanghelle JK, Rand-Hendrikssen S, Strom V, Wilhelmsen JE, Roe C. Pulmonary function, working capacity and strength in young adults with Marfan syndrome. *J Rehabil Med* 2003; 35: 221-228.
83. Karpman C, Aughenbaugh GL, Ryu JH. Pneumothorax and bullae in Marfan syndrome. *Respiration* 2011; 82: 219-224.
84. Lesur O, Delorme N, Fromaget JM, Bernadac P, Polu JM. Computed tomography in the etiologic assessment of idiopathic spontaneous pneumothorax. *Chest* 1990; 98: 341-347.
85. Amjadi K, Alvarez GG, Vanderhelst E, Velkeniers B, Lam M, Noppen M. The prevalence of blebs or bullae among young healthy adults: a thoracoscopic investigation. *Chest* 2007; 132: 1140-1145.
86. Wood JR, Bellamy D, Child AH, Citron KM. Pulmonary disease in patients with Marfan syndrome. *Thorax* 1984; 39: 780-784.
87. Hall JR, Pyeritz RE, Dudgeon DL, Haller JA, Jr. Pneumothorax in the Marfan syndrome: prevalence and therapy. *Ann Thorac Surg* 1984; 37: 500-504.

88. Suzuki T, Akiba T, Miyake R, Marushima H, Morikawa T. Familial spontaneous pneumothorax in two adult siblings with Marfan syndrome. *Ann Thorac Cardiovasc Surg* 2010; 16: 362-364.
89. Yellin A, Shiner RJ, Lieberman Y. Familial multiple bilateral pneumothorax associated with Marfan syndrome. *Chest* 1991; 100: 577-578.
90. Viveiro C, Rocha P, Carvalho C, Zarcos MM. Spontaneous pneumothorax as manifestation of Marfan syndrome. *BMJ Case Rep* 2013; 2013.
91. Sensenig DM, LaMarche P. Marfan's syndrome and spontaneous pneumothorax. *Am J Surg* 1980; 139: 602-604.
92. Habashi JP, Judge DP, Holm TM, Cohn RD, Loeys BL, Cooper TK, Myers L, Klein EC, Liu G, Calvi C, Podowski M, Neptune ER, Halushka MK, Bedja D, Gabrielson K, Rifkin DB, Carta L, Ramirez F, Huso DL, Dietz HC. Losartan, an AT1 antagonist, prevents aortic aneurysm in a mouse model of Marfan syndrome. *Science* 2006; 312: 117-121.
93. Lee JJ, Galatioto J, Rao S, Ramirez F, Costa KD. Losartan Attenuates Degradation of Aorta and Lung Tissue Micromechanics in a Mouse Model of Severe Marfan Syndrome. *Ann Biomed Eng* 2016; 44: 2994-3006.
94. Malfait F, Francomano C, Byers P, Belmont J, Berglund B, Black J, Bloom L, Bowen JM, Brady AF, Burrows NP, Castori M, Cohen H, Colombi M, Demirdas S, De Backer J, De Paepe A, Fournel-Gigleux S, Frank M, Ghali N, Giunta C, Grahame R, Hakim A, Jeunemaitre X, Johnson D, Juul-Kristensen B, Kapferer-Seebacher I, Kazkaz H, Kosho T, Lavallee ME, Levy H, Mendoza-Londono R, Pepin M, Pope FM, Reinstein E, Robert L, Rohrbach M, Sanders L, Sobey GJ, Van Damme T, Vandersteen A, van Mourik C,

- Voermans N, Wheeldon N, Zschocke J, Tinkle B. The 2017 international classification of the Ehlers-Danlos syndromes. *Am J Med Genet C Semin Med Genet* 2017; 175: 8-26.
95. Pope FM, Martin GR, Lichtenstein JR, Penttinen R, Gerson B, Rowe DW, McKusick VA. Patients with Ehlers-Danlos syndrome type IV lack type III collagen. *Proc Natl Acad Sci USA* 1975; 72: 1314-1316.
96. Pepin MG, Murray ML, Byers PH. Vascular Ehlers-Danlos Syndrome. *GeneReviews* 1993.
97. Oderich GS, Panneton JM, Bower TC, Lindor NM, Cherry KJ, Noel AA, Kalra M, Sullivan T, Gloviczki P. The spectrum, management and clinical outcome of Ehlers-Danlos syndrome type IV: a 30-year experience. *J Vasc Surg* 2005; 42: 98-106.
98. Dowton SB, Pincott S, Demmer L. Respiratory complications of Ehlers-Danlos syndrome type IV. *Clin Genet* 1996; 50: 510-514.
99. Hatake K, Morimura Y, Kudo R, Kawashima W, Kasuda S, Kuniyasu H. Respiratory complications of Ehlers-Danlos syndrome type IV. *Leg Med (Tokyo)* 2013; 15: 23-27.
100. McLees BD, Schleiter G, Pinnell SR. Isolation of type III collagen from human adult parenchymal lung tissue. *Biochemistry* 1977; 16: 185-190.
101. Clark JG, Kuhn C, 3rd, Uitto J. Lung collagen in type IV Ehlers-Danlos syndrome: ultrastructural and biochemical studies. *Am Rev Respir Dis* 1980; 122: 971-978.
102. Watanabe A, Shimada T. Vascular type of Ehlers-Danlos syndrome. *J Nippon Med Sch* 2008; 75: 254-261.
103. Murray RA, Poulton TB, Saltarelli MG, Dweik RA, Litwin DK, Kirby TJ, Meziane MA, O'Donovan PB. Rare pulmonary manifestation of Ehlers-Danlos syndrome. *J Thorac Imaging* 1995; 10: 138-141.

104. Corrin B, Simpson CG, Fisher C. Fibrous pseudotumours and cyst formation in the lungs in Ehlers-Danlos syndrome. *Histopathology* 1990; 17: 478-479.
105. Kawabata Y, Watanabe A, Yamaguchi S, Aoshima M, Shiraki A, Hatamochi A, Kawamura T, Uchiyama T, Fukuda Y. Pleuropulmonary pathology of vascular Ehlers-Danlos syndrome: spontaneous laceration, haematoma and fibrous nodules. *Histopathology* 2010; 56: 944-950.
106. Ishiguro T, Takayanagi N, Kawabata Y, Matsushima H, Yoshii Y, Harasawa K, Yamaguchi S, Yoneda K, Miyahara Y, Kagiya N, Tokunaga D, Aoki F, Saito H, Kurashima K, Ubukata M, Yanagisawa T, Sugita Y, Okita H, Hatamochi A. Ehlers-Danlos syndrome with recurrent spontaneous pneumothoraces and cavitary lesion on chest X-ray as the initial complications. *Intern Med* 2009; 48: 717-722.
107. Abrahamsen BJ, Kulseth MA, Paus B. A 19-year-old man with relapsing bilateral pneumothorax, hemoptysis, and intrapulmonary cavitary lesions diagnosed with vascular Ehlers-Danlos syndrome and a novel missense mutation in COL3A1. *Chest* 2015; 147: e166-e170.
108. Dar RA, Wani SH, Mushtaque M, Kasana RA. Spontaneous hemo-pneumothorax in a patient with Ehlers-Danlos syndrome. *Gen Thorac Cardiovasc Surg* 2012; 60: 587-589.
109. Watanabe A, Kosho T, Wada T, Sakai N, Fujimoto M, Fukushima Y, Shimada T. Genetic aspects of the vascular type of Ehlers-Danlos syndrome (vEDS, EDSIV) in Japan. *Circ J* 2007; 71: 261-265.
110. MacCarrick G, Black JH, 3rd, Bowdin S, El-Hamamsy I, Frischmeyer-Guerrerio PA, Guerrerio AL, Sponseller PD, Loeys B, Dietz HC, 3rd. Loeys-Dietz syndrome: a primer for diagnosis and management. *Genet Med* 2014; 16: 576-587.

111. Chambers JE, Dalton LE, Subramanian DN, Gooptu B, Balan A, Park SM, Holden S, Marciniak SJ. Spontaneous pneumothorax can be associated with TGFBR2 mutation. *Eur Respir J* 2015; 46: 1832-1835.
112. Loeys BL, Dietz HC. Loeys-Dietz Syndrome. *GeneReviews* 1993.
113. Sacharow SJ, Picker JD, Levy HL. Homocystinuria Caused by Cystathionine Beta-Synthase Deficiency. 1993.
114. Bass HN, LaGrave D, Mardach R, Cederbaum SD, Fuster CD, Chetty M. Spontaneous pneumothorax in association with pyridoxine-responsive homocystinuria. *J Inherit Metab Dis* 1997; 20: 831-832.
115. Cochran FB, Sweetman L, Schmidt K, Barsh G, Kraus J, Packman S. Pyridoxine-unresponsive homocystinuria with an unusual clinical course. *Am J Med Genet* 1990; 35: 519-522.
116. Berk DR, Bentley DD, Bayliss SJ, Lind A, Urban Z. Cutis laxa: a review. *J Am Acad Dermatol* 2012; 66: 842 e841-817.
117. McCarthy CF, Warin RP, Read AE. Loose Skin (Cutis Laxa) Associated with Systemic Abnormalities. *Arch Intern Med* 1965; 115: 62-67.
118. Genevieve D, Baumann C, Huber C, Faivre L, Sanlaville D, Bodemer C, Hadj-Rabia S, Assoumou A, Verloes A, Raqbi F, Munnich A, Cormier-Daire V. A novel form of syndromic cutis laxa with facial dysmorphism, cleft palate, and mental retardation. *J Med Genet* 2004; 41: e77.
119. Nascimento GM, Nunes CS, Menegotto PF, Raskin S, Almeida N. Cutis laxa: case report. *An Bras Dermatol* 2010; 85: 684-686.
120. Stoller JK, Lacbawan FL, Aboussouan LS. Alpha-1 Antitrypsin Deficiency. 1993.

121. Gishen P, Saunders AJ, Tobin MJ, Hutchison DC. Alpha 1-antitrypsin deficiency: the radiological features of pulmonary emphysema in subjects of Pi type Z and Pi type SZ: a survey by the British Thoracic Association. *Clin Radiol* 1982; 33: 371-377.
122. Needham M, Stockley RA. Alpha 1-antitrypsin deficiency. 3: Clinical manifestations and natural history. *Thorax* 2004; 59: 441-445.
123. Mostafavi S, Lieberman J. Intermediate alpha 1-antitrypsin deficiency with apical lung bullae and spontaneous pneumothorax. Presence of a Z variant in an American black. *Chest* 1991; 99: 1545-1546.
124. Carrell RW, Lomas DA. Alpha 1-antitrypsin deficiency--a model for conformational diseases. *N Engl J Med* 2002; 346: 45-53.
125. The Alpha-1-Antitrypsin Deficiency Registry Study Group. Survival and FEV1 decline in individuals with severe deficiency of alpha1-antitrypsin. The Alpha-1-Antitrypsin Deficiency Registry Study Group. *Am J Respir Crit Care Med* 1998; 158: 49-59.
126. Larsson C. Natural history and life expectancy in severe alpha1-antitrypsin deficiency, Pi Z. *Acta Med Scand* 1978; 204: 345-351.
127. Tanash HA, Nilsson PM, Nilsson JA, Piitulainen E. Survival in severe alpha-1-antitrypsin deficiency (PiZZ). *Respir Res* 2010; 11: 44.
128. Lin YC, Chiu WK, Chang H, Cheng YL, Chen JC. Spontaneous pneumothorax in flight as first manifestation of alpha-1 antitrypsin deficiency. *Aviat Space Environ Med* 2008; 79: 704-706.
129. Lepiorz M, Grosser C, Hofmann HS, Pfeifer M. [A Rare Cause of a Spontaneous Pneumothorax]. *Pneumologie* 2017; 71: 590-593.
130. Sakula A. Antitrypsin deficiency in lung disease. *Lancet* 1970; 1: 302-303.

131. Eriksson S. Studies in alpha 1-antitrypsin deficiency. *Acta Med Scand Suppl* 1965; 432: 1-85.
132. Pawlowicz A, Droszcz W. Pulmonary function and alpha-1-antitrypsin levels in patients after so-called idiopathic spontaneous pneumothorax. *Bull Eur Physiopathol Respir* 1987; 23: 1-4.
133. Serapinas D, Obrikyte V, Vaicius D, Balciuviene R, Valavicius A, Sakalauskas R. Alpha-1 antitrypsin deficiency and spontaneous pneumothorax: possible causal relationship. *Pneumologia* 2014; 63: 32-35.
134. Janus ED, Phillips NT, Carrell RW. Smoking, lung function, and alpha 1-antitrypsin deficiency. *Lancet* 1985; 1: 152-154.
135. Kioumis IP, Zarogoulidis K, Huang H, Li Q, Dryllis G, Pitsiou G, Machairiotis N, Katsikogiannis N, Papaiwannou A, Lampaki S, Porpodis K, Zaric B, Branislav P, Mpoukovinas I, Lazaridis G, Zarogoulidis P. Pneumothorax in cystic fibrosis. *J Thorac Dis* 2014; 6: S480-487.
136. Flume PA, Strange C, Ye X, Ebeling M, Hulsey T, Clark LL. Pneumothorax in cystic fibrosis. *Chest* 2005; 128: 720-728.
137. Hafen GM, Ukoumunne OC, Robinson PJ. Pneumothorax in cystic fibrosis: a retrospective case series. *Arch Dis Child* 2006; 91: 924-925.
138. Spector ML, Stern RC. Pneumothorax in cystic fibrosis: a 26-year experience. *Ann Thorac Surg* 1989; 47: 204-207.
139. Rich RH, Warwick WJ, Leonard AS. Open thoracotomy and pleural abrasion in the treatment of spontaneous pneumothorax in cystic fibrosis. *J Pediatr Surg* 1978; 13: 237-242.
140. Flume PA. Pneumothorax in cystic fibrosis. *Chest* 2003; 123: 217-221.

141. McLaughlin FJ, Matthews WJ, Jr., Strieder DJ, Khaw KT, Schuster S, Shwachman H. Pneumothorax in cystic fibrosis: management and outcome. *J Pediatr* 1982; 100: 863-869.
142. De Rose AF, Giglio M, Gallo F, Romano L, Carmignani G. Congenital bilateral absence of the vasa deferentia and related respiratory disease. *Arch Ital Urol Androl* 2003; 75: 214-216.
143. Castellani C, Quinzii C, Altieri S, Mastella G, Assael BM. A pilot survey of cystic fibrosis clinical manifestations in CFTR mutation heterozygotes. *Genet Test* 2001; 5: 249-254.
144. Henry M, Arnold T, Harvey J, Pleural Diseases Group SoCCBTS. BTS guidelines for the management of spontaneous pneumothorax. *Thorax* 2003; 58 Suppl 2: ii39-52.
145. Curtis HJ, Bourke SJ, Dark JH, Corris PA. Lung transplantation outcome in cystic fibrosis patients with previous pneumothorax. *J Heart Lung Transplant* 2005; 24: 865-869.
146. Rosenblatt RL. Lung transplantation in cystic fibrosis. *Respir Care* 2009; 54: 777-786; discussion 786-777.
147. Flume PA, Mogayzel PJ, Jr., Robinson KA, Rosenblatt RL, Quittell L, Marshall BC, Clinical Practice Guidelines for Pulmonary Therapies C, Cystic Fibrosis Foundation Pulmonary Therapies C. Cystic fibrosis pulmonary guidelines: pulmonary complications: hemoptysis and pneumothorax. *Am J Respir Crit Care Med* 2010; 182: 298-306.
148. Balasubramanian M, Shearing E, Smith K, Chavasse R, Taylor R, Tatton-Brown K, Primhak R, Ugonna K, Parker MJ. Pneumothorax from subpleural blebs-a new association of sotos syndrome? *Am J Med Genet A* 2014; 164A: 1222-1226.
149. Fukazawa T, Sasaki H, Kikuchi S, Hamada K, Hamada T, Tashiro K. Spinocerebellar ataxia type 1 and familial spontaneous pneumothorax. *Neurology* 1997; 49: 1460-1462.

150. Stanley SE, Chen JJ, Podlevsky JD, Alder JK, Hansel NN, Mathias RA, Qi X, Rafaels NM, Wise RA, Silverman EK, Barnes KC, Armanios M. Telomerase mutations in smokers with severe emphysema. *J Clin Invest* 2015; 125: 563-570.
151. Witkop CJ, Jr., White JG, King RA, Dahl MV, Young WG, Sauk JJ, Jr. Hereditary mucoepithelial dysplasia: a disease apparently of desmosome and gap junction formation. *Am J Hum Genet* 1979; 31: 414-427.
152. Tsai AP, English JC, Murphy D, Sin DD. Recurrent pneumothorax related to diffuse dendriform pulmonary ossification in genetically predisposed individual. *Respirol Case Rep* 2017; 5: e00211.
153. MacDuff A, Arnold A, Harvey J. Management of spontaneous pneumothorax: British Thoracic Society Pleural Disease Guideline 2010. *Thorax* 2010; 65 Suppl 2: ii18-31.
154. Baumann MH, Strange C, Heffner JE, Light R, Kirby TJ, Klein J, Luketich JD, Panacek EA, Sahn SA. Management of spontaneous pneumothorax: an American College of Chest Physicians Delphi consensus statement. *Chest* 2001; 119: 590-602.
155. Menko FH, Johannesma PC, van Moorselaar RJ, Reinhard R, van Waesberghe JH, Thunnissen E, Houweling AC, Leter EM, Waisfisz Q, van Doorn MB, Starink TM, Postmus PE, Coull BJ, van Steensel MA, Gille JJ. A de novo FLCN mutation in a patient with spontaneous pneumothorax and renal cancer; a clinical and molecular evaluation. *Fam Cancer* 2013; 12: 373-379.
156. Gupta N, Langenderfer D, McCormack FX, Schauer DP, Eckman MH. Chest Computed Tomographic Image Screening for Cystic Lung Diseases in Patients with Spontaneous Pneumothorax Is Cost Effective. *Ann Am Thorac Soc* 2017; 14: 17-25.

157. Gupta N. Primary Spontaneous Pneumothorax: Looking Beyond the Usual. *Acad Emerg Med* 2018; 25: 470-472.
158. Kunogi M, Kurihara M, Ikegami TS, Kobayashi T, Shindo N, Kumasaka T, Gunji Y, Kikkawa M, Iwakami S, Hino O, Takahashi K, Seyama K. Clinical and genetic spectrum of Birt-Hogg-Dube syndrome patients in whom pneumothorax and/or multiple lung cysts are the presenting feature. *J Med Genet* 2010; 47: 281-287.
159. Northrup H, Krueger DA. Tuberous sclerosis complex diagnostic criteria update: recommendations of the 2012 International Tuberous Sclerosis Complex Consensus Conference. *Pediatr Neurol* 2013; 49: 243-254.
160. Loeys BL, Dietz HC, Braverman AC, Callewaert BL, De Backer J, Devereux RB, Hilhorst-Hofstee Y, Jondeau G, Faivre L, Milewicz DM, Pyeritz RE, Sponseller PD, Wordsworth P, De Paepe AM. The revised Ghent nosology for the Marfan syndrome. *J Med Genet* 2010; 47: 476-485.
161. Morris AA, Kozich V, Santra S, Andria G, Ben-Omran TI, Chakrapani AB, Crushell E, Henderson MJ, Hochuli M, Huemer M, Janssen MC, Maillot F, Mayne PD, McNulty J, Morrison TM, Ogier H, O'Sullivan S, Pavlikova M, de Almeida IT, Terry A, Yap S, Blom HJ, Chapman KA. Guidelines for the diagnosis and management of cystathionine beta-synthase deficiency. *J Inherit Metab Dis* 2017; 40: 49-74.
162. Sandhaus RA, Turino G, Brantly ML, Campos M, Cross CE, Goodman K, Hogarth DK, Knight SL, Stocks JM, Stoller JK, Strange C, Teckman J. The Diagnosis and Management of Alpha-1 Antitrypsin Deficiency in the Adult. *Chronic Obstr Pulm Dis* 2016; 3: 668-682.
163. Farrell PM, Rosenstein BJ, White TB, Accurso FJ, Castellani C, Cutting GR, Durie PR, Legrys VA, Massie J, Parad RB, Rock MJ, Campbell PW, 3rd. Guidelines for diagnosis of

- cystic fibrosis in newborns through older adults: Cystic Fibrosis Foundation consensus report. *J Pediatr* 2008; 153: S4-S14.
164. DeMartino ES, Wieland CN, Allen MS, Utz JP. What Pneumothoraces and Fibrofolliculomas Convey: Birt-Hogg-Dube. *Am J Respir Crit Care Med* 2016; 194: 634-635.
165. De Maio F, Fichera A, De Luna V, Mancini F, Caterini R. Orthopaedic Aspects of Marfan Syndrome: The Experience of a Referral Center for Diagnosis of Rare Diseases. *Adv Orthop* 2016; 2016: 8275391.
166. Sridhar J, Chang JS. Marfan's Syndrome with Ectopia Lentis. *N Engl J Med* 2017; 377: 1076.
167. Sobey G. Ehlers-Danlos syndrome: how to diagnose and when to perform genetic tests. *Arch Dis Child* 2015; 100: 57-61.
168. Vilacosta I, Canadas Godoy V. Images in clinical medicine. Bifid uvula and aortic aneurysm. *N Engl J Med* 2008; 359: e2.
169. Stoller JK, Aboussouan LS. A review of alpha1-antitrypsin deficiency. *Am J Respir Crit Care Med* 2012; 185: 246-259.
170. Morava E, Guillard M, Lefeber DJ, Wevers RA. Autosomal recessive cutis laxa syndrome revisited. *Eur J Hum Genet* 2009; 17: 1099-1110.
171. Sweetser DA, Lin AE, Troulis MJ, Chen TC, Westra SJ. Case 34-2016. A 17-Year-Old Boy with Myopia and Craniofacial and Skeletal Abnormalities. *N Engl J Med* 2016; 375: 1879-1890.
172. Kaliaperumal S, Kumar KP. Varied phenotypic presentations of homocystinuria in two siblings. *Indian J Ophthalmol* 2014; 62: 93-94.

173. Ha SM, Yoon HK, Lee SK. Rare Lung Manifestation of Multifocal Micronodular Pneumocyte Hyperplasia in a Teenage Girl with Tuberous Sclerosis Complex. *J Korean Soc Radiol* 2016; 75: 133-137.

Table 1. Mendelian diseases associated with spontaneous pneumothorax.

AD, autosomal dominant. AR, autosomal recessive. P or PTX, pneumothorax. C, cysts.

Condition / Inheritance pattern	Pulmonary features (in addition to pneumothorax)	Extrapulmonary features	Penetrance (PTX/Cysts)	Gene(s)	Diagnostic criteria
<i>Syndromes resulting from mutated tumor suppressor genes</i>					
Birt-Hogg-Dubé syndrome AD	Cysts: Elliptical or lentiform, with predominantly basilar, medial, and subpleural distribution	Skin lesions: Fibrofolliculomas, trichodiscomas, acrochordons (skin tags) Renal cancer: Renal cell carcinomas, oncocytomas, and others	P: 22-41% C: 83-100%	<i>FLCN</i>	(29)
Tuberous sclerosis complex AD	LAM: Cysts, bullae, reticulonodular infiltrates, pleural effusions, obstructive physiology; female predominance Micronodular pneumocyte hyperplasia	Brain: Subependymal nodules, cortical dysplasia (tubers), cerebral white matter migration lines, subependymal giant cell astrocytomas, seizures or infantile spasms, developmental delay/intellectual disability, autism, ADHD Skin: Hypopigmented macules (ash leaf spots), Shagreen patches, confetti lesions, facial angiofibromas, fibrous cephalic plaques, ungual fibromas Kidney: Angiomyolipomas (renal or extra-renal), renal cysts, renal cell carcinomas & oncocytomas Heart: Rhabdomyomas, arrhythmias Eye: Retinal nodular hamartomas, achromic retinal patches Mouth: Dental pits, intraoral fibromas	In LAM: P: 56-66% C: ~100%	<i>TSC2</i> <i>TSC1</i>	(159)
<i>Syndromes of disordered connective tissue</i>					
Marfan syndrome AD	Lungs usually normal; rare features include: Cysts Emphysema Congenital lung malformations Increased TLC and RV	Skeletal: Tall, thin habitus, ↓ upper:lower segment ratio, reduced elbow extension, arachnodactyly, hand/wrist signs, pectus excavatum/carinatum, scoliosis/kyphosis, hindfoot deformity, flat feet Facial features: Dolichocephaly, down-slanting palpebral fissures, enophthalmos, retrognathia, malar hypoplasia Eye: Lens dislocation, severe myopia Skin: Striae Cardiac: Aortic dilation/dissection/aneurysm/ rupture, mitral valve prolapse	P: 4-11% C: 10% (bullae / blebs)	<i>FBN1</i>	(160)
Vascular (type IV) Ehlers Danlos syndrome AD	Cavitary lesions Cysts, bullae Fibrous nodules with osseous metaplasia	Vascular: Arterial aneurysm, dissection, rupture, carotid-cavernous sinus fistula Organ rupture: of colon or gravid uterus	P: 16-80%	<i>COL3A1</i>	(94)

	Hemo-pneumothorax or pulmonary hemorrhage	Facial appearance: Thin lips and nose, micrognathia, prominent eyes Skin: Translucent skin with visible veins, easy bruising Orthopedic: Clubfoot, congenital hip dislocation, lax small joints, muscle/tendon rupture			
Loeys-Dietz syndrome AD	N/A	Vascular: Arterial aneurysms, dissection, tortuosity Skeletal: Pectus excavatum or carinatum, joint laxity or contractures, cervical spine instability, scoliosis, arachnodactyly, club foot Craniofacial: Bifid uvula or cleft palate, hypertelorism, retrognathia Cutaneous: Translucent or dystrophic skin, easy bruising Uterine rupture	Unknown	<i>TGFBR1</i> <i>TGFBR2</i> <i>SMAD3</i> <i>TGFB2</i> <i>TGFB3</i> <i>SMAD2</i>	None
Homocystinuria AR	N/A	Skeletal: Marfanoid habitus Eye: Dislocated lens, myopia Neurologic: Intellectual disability, seizures Vascular: Thrombosis	Unknown	<i>CBS</i>	(161)
Cutis laxa* AD/AR *Note that features vary by subtype.	Bronchiectasis Emphysema	Cutaneous: Redundant, loose, hypoelastic skin Facial: Aged appearance Vascular: Aortic aneurysms, tortuosity Musculoskeletal: Joint laxity, scoliosis Other: Hernias	Unknown	<i>ELN</i> <i>FBLN4</i> <i>FBLN5</i> <i>LTBP4</i>	N/A
<i>Syndromes that disrupt lung architecture</i>					
Alpha-1-antitrypsin deficiency AR	Panacinar emphysema Bullae Bronchiectasis Obstruction	Liver : Cirrhosis, hepatocellular carcinoma, neonatal cholestatic jaundice Skin: Panniculitis Inflammatory: Vasculitis	Unknown	<i>SERPIN A1</i>	(162)
Cystic fibrosis AR	Bronchiectasis Bacterial colonization/infection Cysts/cavitations Obstruction Respiratory failure	GI: Meconium ileus, pancreatic insufficiency, pancreatitis, malabsorption, failure to thrive Male infertility ENT: Nasal polyps, sinus disease	P: 8%	<i>CFTR</i>	(163)

Figures

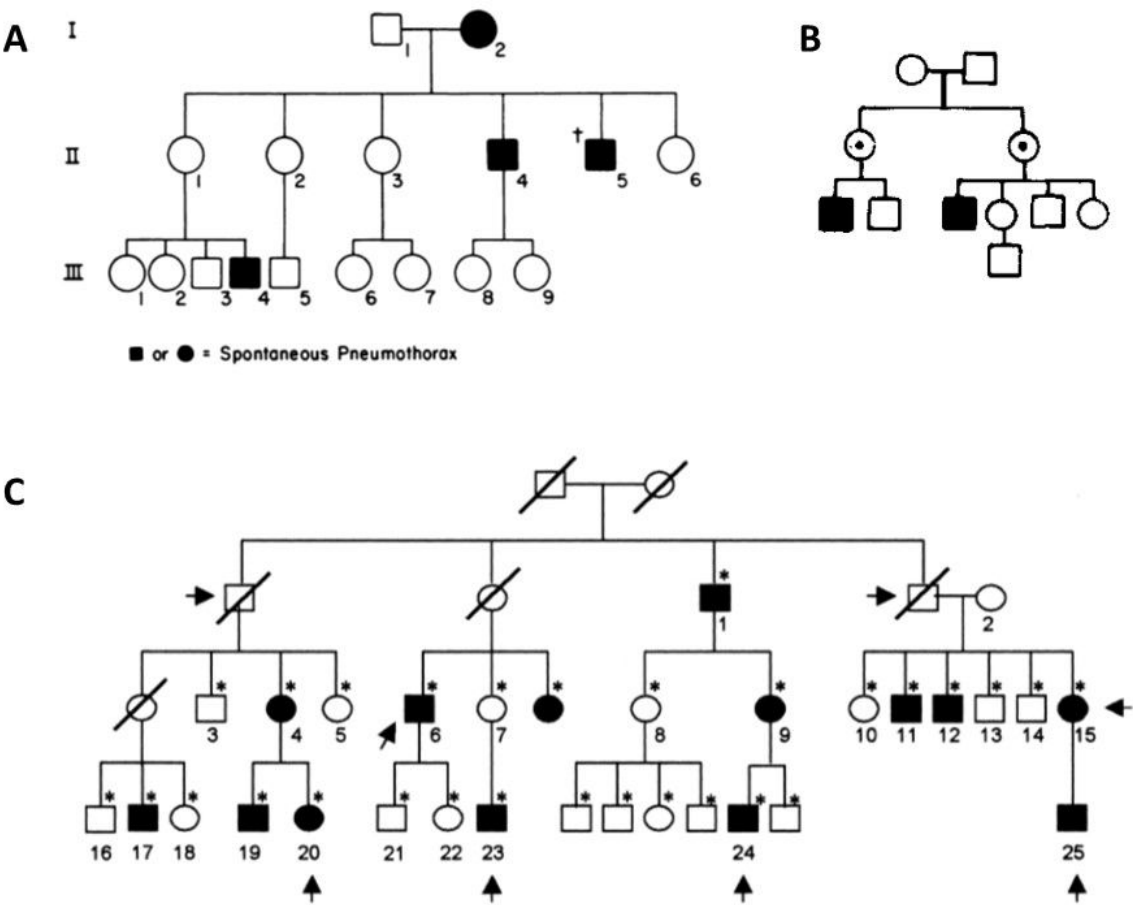


Figure 1. Pedigrees demonstrating familial spontaneous pneumothorax. a. Most pedigrees are consistent with autosomal dominant inheritance with incomplete penetrance. No causal gene reported for this family. Circles, females; squares, males; shaded, pneumothorax. Reproduced from (21). **b.** Some pedigrees are also consistent with X-linked recessive inheritance (versus AD with reduced penetrance in females). No causal gene reported for this family. Dot, obligate carrier. Reproduced from (4) **c.** Family with known *FLCN* mutation. CT lung findings (black shading) are more clearly autosomal dominant than pneumothorax (arrows). Individual 23 has a different bullae phenotype (apical instead of random distribution) and is mutation negative, likely explaining why

his mother does not have bullae (different cause of pneumothorax in this branch of family). *, CT lung performed; diagonal line, deceased. Reproduced from (26).

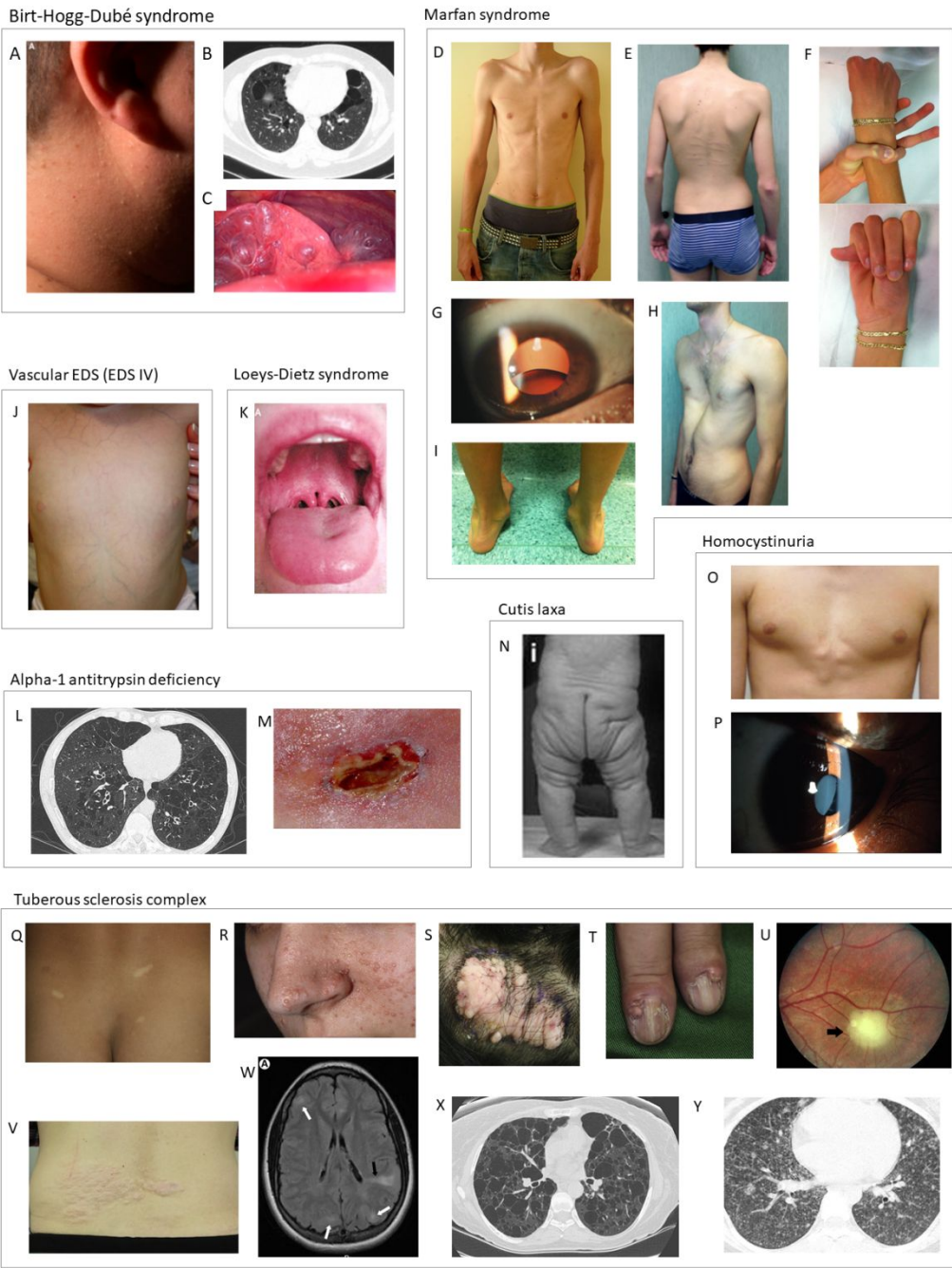


Figure 2. Physical exam findings of pneumothorax-associated syndromes. (a-c) Birt-Hogg-Dubé syndrome (BHDS). **a.** Fibrofolliculomas of the neck (164). **b.** Lung cysts and bullae; extra-apical location is characteristic (164). **c.** Pleural blebs on the surface of the left lower lobe; these can be missed on CT but seen during thoracoscopy/VATS (164). **(d-j)** Marfan syndrome. **d.**

Marfanoid body habitus (90). **e.** Scoliosis, striae, reduced elbow extension (165). **f.** Positive thumb and wrist signs indicating arachnodactyly (165). **g.** Lens dislocation (166). **h.** Pectus excavatum (165). **i.** Hindfoot deformity (165). **(j)** Vascular (type IV) EDS. **j.** Translucent skin on the torso of an infant (167). **(k)** Loeys-Dietz syndrome. **k.** Bifid uvula (168) **(l-m)** Alpha-1-antitrypsin deficiency. **l.** Panlobular emphysema (case courtesy of Dr. Jeremy Jones, Radiopaedia.org, rID:13441). **m.** Panniculitis (169). **(n)** Cutis laxa. **n.** Autosomal recessive cutis laxa IIa (170). **(o-p)** Homocystinuria. **o.** Chest wall deformity (171). **p.** Lens dislocation (172). **(q-y)** Tuberous sclerosis complex. **q.** hypopigmented macules (ash leaf spots) (159). **r.** angiofibromas (159). **s.** fibrous plaques (159). **t.** Ungual fibromas (159). **u.** Retinal hamartoma (159). **v.** Shagreen patch (159). **w.** Cortical dysplasia (tubers, white arrows; radial migration lines, black arrows) (159). **x.** Lymphangioleiomyomatosis (159). **y.** Multifocal micronodular pneumocyte hyperplasia (173). Images are reproduced from the sources cited above.

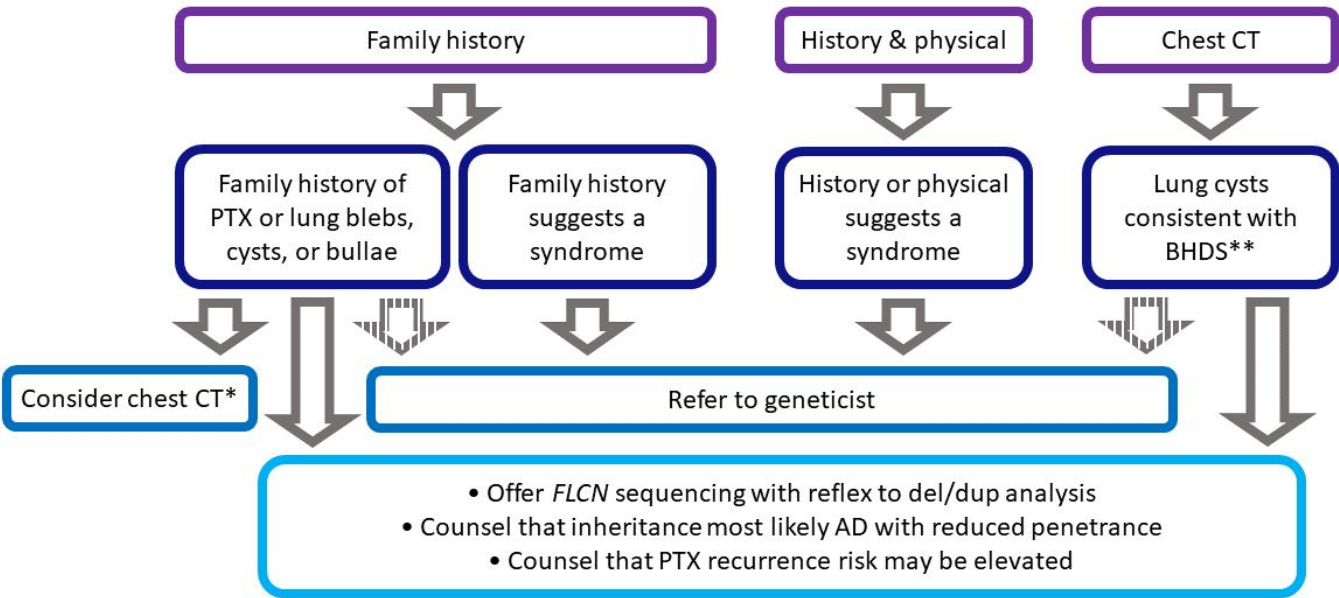


Figure 3. Proposed algorithm for identifying spontaneous pneumothoraces with a genetic basis. Algorithm should be applied to all patients with spontaneous pneumothorax. Dashed arrows are optional, based on the practitioner’s comfort. **FLCN* testing in cases of absent family history is still reasonable, so long as a chest CT, if previously obtained, is not inconsistent with BHDs. **Chest CT findings in BHDs include bilateral, multifocal, predominately lower-lobe cysts.

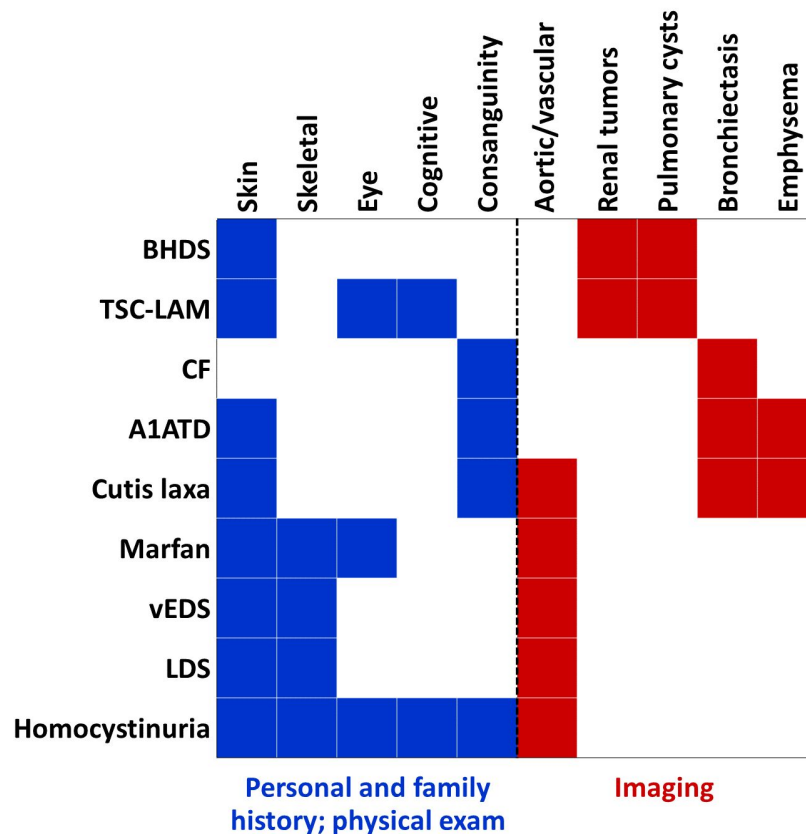


Figure 4. History, physical exam, and imaging findings that raise the possibility of a syndromic cause of pneumothorax. Syndromes predisposing to pneumothorax (X-axis) are intersected with their major features (Y-axis). Personal history/ family history/ physical exam findings are in blue. Imaging findings are in maroon. The skin findings of BHDS are age dependent; thus, skin exams of the parents or even grandparents may at times more informative than for the proband. BHDS, Birt-Hogg-Dubé syndrome; TSC-LAM, lymphangioleiomyomatosis in an individual with tuberous sclerosis; CF, cystic fibrosis; A1ATD, alpha-1-antitrypsin deficiency; vEDS, vascular Ehlers-Danlos syndrome; LDS, Loeys-Dietz syndrome.