VETERINARY SURGERY

Evaluation of 3 Human Cervical Fusion Implants for use in the Canine Cervical Vertebral Column

Journal:	*Veterinary Surgery*
Manuscript ID	VSU-15-229.R1
Manuscript Type:	Original Article - Research
Keywords:	dog, cervical vertebral column, interbody cage, Zero-P, Uniplate

ABSTRACT

Objective: To assess technical feasibility and mechanical properties of three locking plate designs (Zero-P, Zero-P VA and Uniplate 2) for use in the canine cervical spine.

Study Design: Prospective ex-vivo study using canine cadaveric tissues.

Animals: Eighteen canine cervical spines collected from skeletally mature large-breed dogs.

Methods: Specimens were screened using radiography and allocated into balanced groups based on bone density. Stiffness of intact C4–C5 vertebral motion units (VMU) was measured in extension, flexion and lateral bending using non-destructive 4-point bend testing. Uniplate 2 was then implanted at C4-C5 and mechanical testing was repeated. Mechanical test data were compared against those from six spines implanted with monocortical screws, an allograft ring spacer and PMMA.

Results: The Zero-P and Zero-P VA systems could not be surgically implanted due to anatomical constraints of the canine cervical spine. Fixation with Uniplate 2 or with screws/PMMA significantly increased stiffness of the C4-C5 VMU compared to unaltered specimens ($p < 0.001$) in extension. Stiffness of the titanium screw/PMMA fixation was significantly greater than the Uniplate 2 construct in this direction. Flexion and lateral bending could not be evaluated in 3 of 6 specimens in the Uniplate 2 group due to failure at the bone/implant interface during extension testing.

Conclusions: Fixation with Uniplate 2 was biomechanically inferior to screws/PMMA. Particularly concerning was the incidence of vertebral fracture after several testing cycles. Fixation using the Zero-P and Zero-P VA was unsuccessful due to anatomic constraints in the vertebral column sizes used in this study.

INTRODUCTION

Canine cervical spondylomyelopathy (CCSM) is a common, naturally occurring and progressive disorder affecting large and giant-breed dogs. The pathophysiology and clinical sequelae of CCSM in dogs are similar to those of compressive cervical myelopathy in humans.[1]

Surgical stabilization of the cervical vertebral column in dogs affected with CCSM has become a promising treatment option, and has been largely modeled from human medicine.[1-10] One option for surgical treatment involves distraction of the affected intervertebral articulation to relieve soft tissue compression of the spinal cord, followed by stabilization to attain bony fusion across the site. While a multitude of techniques and implants have been developed for human cervical fusion, the development of canine spine specific veterinary implants is still in its infancy, with most available literature based on case reports and few biomechanical studies.[8-10]

A range of standard veterinary orthopedic implants have been adapted for use in the canine cervical vertebral column. Clinical and biomechanical reports of locking plates used with monocortical screws and monocortical screw/polymethylmethacrylate constructs support their use in dogs.[1,5, 9-13] Avoiding use of PMMA in fixation methods could be beneficial in preventing complications associated with this material including thermal injury during curing, increased risk of infection, cement failure, bulky material with possible soft tissue compression, and difficult removal.[1,5,7,13] Utilization of locking

plates could eliminate many of the disadvantages of PMMA and offer rigid fixation with a low profile and the ability to use monocortical screws.

Two clinical studies have evaluated human fusion plate systems in canine patients.[1,10] Bergman[10] evaluated a cervical spine locking plate (CSLP; Synthes) combined with a cortical ring allograft and cancellous autograft in 10 dogs. Of the 8 dogs that were available for follow-up, 7 had moderate to complete improvement and did not experience recurrence at long term follow-up (approximately 2.5 years). Trotter[1] also evaluated the use of CSLP, this time with cancellous block interbody grafting, and reported satisfactory outcomes in 8 of 10 dogs at long term follow-up of 1-5 years. Complications encountered with the use of the CSLP in the canine spine related to the highly variable shape of the ventral aspect of the canine cervical vertebrae which required increased time to contour and bend the plate—it was hypothesized that such changes may contribute to complications such as screw loosening via alteration of the plate's biomechanical efficacy.[10]

Given the inherent costs associated with manufacturing implants specifically for the canine market, it would clearly be advantageous to be able to make use of standard human implants in dogs. Differences in spinal dimensions and anatomy between humans and dogs make this challenging, especially in the cervical spine.[1] Locking plate designs offer some advantages in this regard since they do not rely on absolutely accurate contouring between the plate and the underlying bone structures. With this in mind, we

wanted to explore the potential utility of three contemporary locking plate designs: Zero-P and Zero-P VA and Uniplate 2 (DePuy Orthopaedics, Inc., Warsaw, Indiana, USA).

The Zero-P implant is a stand-alone implant designed for cervical interbody fusion in humans with degenerative disc disease and spinal stenosis.[14] It features a radiopaque PEEK interbody spacer of variable height and angle, and a titanium alloy interbody plate that accepts four 2.4mm self-tapping titanium alloy locking screws (2 screws in cranial and 2 screws in caudal orientation).[14] (Figures 1 and 2A).

The Zero-P VA uses the same PEEK interbody spacer; however, the interbody plate only allows two 3.7mm titanium alloy screws for fixation (one screw each for cranial and caudal fixation).[15] These are variable angle screws that can be oriented in wider trajectories than the locking screws used in the Zero-P, potentially facilitating bony purchase in the vertebral bodies.[15] (Figures 1 and 2B).

Several biomechanical reports have been performed in humans to evaluate the Zero-P and Zero-P VA implants for use in cervical interbody fusion. One biomechanical study suggested that a spacer implant with locked screws (Zero P) significantly reduces motion compared to an intact spine, while a variable angle screw spacer failed to provide adequate stabilization for the same type of injury.[16] Additionally, it was reported that anchored cage implants (the Zero-P) had similar clinical outcomes to that of a cage combined with a plate, but were inferior in stabilization of motion and rates of fusion.[17]

The Uniplate 2 system is a low profile 2-hole locking titanium plate developed to hasten operative times and reduce soft tissue dissection around the vertebral body [18] (Figure 1 and 2C). It relies on fixation with only one screw per vertebral level (monovertebral monocortical fixation). Limited reports in the human literature suggest equivalent biomechanical efficacy of the similarly designed Uniplate™ (Depuy Spine, Raynham, MA, USA) to other plates that utilize one screw per vertebral level.[19]

To the authors' knowledge, none of these 3 implants have been evaluated for either technical feasibility or for biomechanical effect in the canine cervical spine. If usable and efficacious, they may offer alternative options for dogs requiring cervical distraction and fusion using spine-specific implants. The goal of this study was therefore to evaluate the two Zero-P designs (used with the standard PEEK spacer) and the Uniplate 2 (used with a cortical ring allograft spacer) in the canine cervical vertebral column. Biomechanical testing was performed and the results compared to those of an established monocortical titanium screw(Ti)/PMMA (polymethylmethacrylate)/cortical ring construct. Our hypothesis was that the human implants could be applied to the canine cervical vertebral column and that there would be no significant difference in the stiffness between them and the Titanium/polymethylmethacrylate ring construct.

MATERIALS AND METHODS

The study was reviewed and approved by the local Institutional Laboratory Animal Care and Use Committee.

Tissue Specimens

Canine cervical vertebral columns (C2–C7) were harvested from mature dogs (n = 18) that had been euthanatized for reasons unrelated to this study. To be included, dogs had to weigh 20–31 kg. Orthogonal radiographs were obtained to ensure physeal closure and lack of pathology affecting the vertebrae and disk spaces. Vertebral bone mineral density measurements were made by dual‐energy X‐ray absorptiometry (DEXA) scans (Lunar Prodigy; GE Healthcare, Milwaukee, WI) and these data were used to allocate specimens into three balanced groups. Surrounding soft tissues were resected except for vertebral musculature, joint capsules and ligaments associated with vertebrae C3–C6. Specimens were then wrapped in moist towels, soaked in sterile saline (0.9% NaCl) solution, and frozen until testing. Specimens were kept moist using sterile saline solution during processing and testing.

Biomechanical Testing

The cervical vertebral columns were thawed to room temperature, the vertebral motion units (VMUs) between C3–C4 and C5–C6 were immobilized using previously described methods[12] and an extensometer applied across C4-C5. The operated C4-C5 motion unit was then tested in extension, flexion and right lateral bending using a custom made, four‐point bending fixture with a previously reported protocol.[12,20] Briefly, after a

preload of 5 Newtons (N), testing was conducted under load control at 50 N/min to 150 N in flexion and extension and to 100 N in right lateral bending. Each specimen sequentially underwent 4 full cycles of extension, flexion, and lateral bending with load and displacement data from the 4th cycle data used for analysis when available. Load and extensometer displacement data were used to calculate load– displacement curves for each bending moment of the intact C4–C5 motion unit. Stiffness (N/mm) was determined by calculating the slope of the linear portion of each load–displacement curve. After testing was completed for the intact specimen, the spinal instrumentation was applied (see below) and testing repeated on the instrumented C4-C5 levels.

Instrumentation of the C4-C5 motion unit

Six specimens were initially used to evaluate the Zero-P and Zero-P VA implants. After a standard ventral approach to the mid cervical spine, a diskectomy was performed at C4-C5 and the disk space was manually distracted. A 5mm height parallel PEEK ring was inserted into the disk space with the appropriate interbody plate attached.

For the Zero-P implant, (DePuy Orthopaedics, Inc.,Warsaw, Indiana, USA), a threaded drill guide was used and holes were drilled with a 1.8 mm drill and the plate secured with four 2.4mm stainless steel self-tapping locking screws, 2 placed in the cranial vertebra and 2 in the caudal vertebra. For the Zero-P VA implant, a 2.5 mm awl with variable angle sleeve was used to create a pilot hole into the caudal endplate bone of C4 and cranial endplate bone of C5 prior to screw insertion. Two 3.7 mm self-drilling titanium alloy screws were then placed into the cranial and caudal vertebral endplate with a

stardrive screwdriver. None of these 6 spines proved to be stable and further testing of these 2 devices was abandoned (Figures 2A and B).

The Uniplate 2 implant (DePuy Orthopaedics, Inc.,Warsaw, Indiana, USA) was successfully deployed in 6 of 6 test specimens. A standard approach to the ventral aspect of C4–C5 was performed. After diskectomy and manual distraction, a cortical ring allograft of appropriate size, harvested previously from canine cadaveric tibiae, was placed into the C4-C5 intervertebral disk space. The Uniplate 2 was placed to span the intervertebral space, ensuring that screw holes and subsequent screws would avoid the disk space. Plate contouring was also used to optimize the fit between the plate and the underlying bone. An awl was used to penetrate the cis cortex and mark position of the screw hole, then a 3.2mm drill bit was used to drill through the cis cortex only. A 4.6 mm self-drilling screw was then inserted monocortically into the C4 and C5 vertebral body. The screws were locked via a cam-lock technique using the CAM-LOC and tightened using the CAM Tightener Shaft (DePuy Orthopaedics, Inc) until an audible click occurred, signaling that the proper level of torque had been reached (Figure 2C).

In order to provide clinical context for these biomechanical tests, comparisons were made against a series of 6 cervical vertebral specimens that were implanted with screw/PMMA and an interbody spacer as part of an earlier study.[12] These specimens had been harvested under the same inclusion criteria and procedural protocols, and had undergone C4-C5 stabilization with cortical ring disk spacer and 3.5 mm monocortical self-tapping titanium

screws with 20 g of PMMA per specimen (DePuy Synthes Vet, West Chester, PA and Simplex P Bone Cement, Stryker, Mahwah, NJ, respectively).

Postoperative Implant Assessment

Post-implantation and post-testing orthogonal radiographic projections were used to assess implant position and to identify any evidence of mechanical failure at the implant-bone interface or within the bone itself (Figure 2).

Statistical Analysis

Descriptive statistics were calculated for all variables. Baseline characteristics between the Uniplate 2 and Titanium screw/PMMA fixation were compared using Fisher exact tests for categorical data and Student's t tests for quantitative data. Stiffness was compared between spines fixed with the Uniplate versus titanium screw/PMMA and evaluated among the 3 directional measurements (i.e., extension, flexion, and lateral bending). Ninety-five percent mid-P exact confidence intervals (CI) were calculated for each measurement. Statistical testing was performed using commercially available software (IBM SPSS Statistics, Version 22, International Business Machines Corp., Armonk, NY) and significance was set at $p < 0.05$.

RESULTS

Vertebral Specimens

Spines of 6 large breed dogs were used to apply the Zero-P and Zero-P VA to mid and caudal cervical VMUs. The 5mm parallel PEEK cage could be applied without difficulty. Screws into the caudal vertebra appeared well positioned; however, screws in the cranial vertebra did not achieve adequate bony purchase for either implant. Most screws only penetrated a small amount of the caudal endplate of C4 at the ventral aspect. At best, they purchased bone at the caudal base of the transverse process of C4. Fixation was deemed inappropriate and biomechanical testing was not performed.

Twelve cervical vertebral column specimens were used for biomechanical testing of the Uniplate 2 (n=6) and the titanium screw/PMMA construct (n=6). All specimens were from Pit Bull terriers that were skeletally mature, as determined by radiographic evidence of physeal closure, and free of evidence of vertebral pathology. There were 6 intact male and 6 intact female dogs and body weight ranged from 22-30 kg. There was no significant difference in body weight, gender or bone mineral density between these 2 groups.

Biomechanical Testing

In the Uniplate 2 group, all of the intact specimens were successfully tested in extension, flexion and lateral bending. The instrumented specimens were all successfully tested in extension, but flexion and lateral bending data were not available in 3 of the fixed

specimens due to overt failure in extension. The titanium screw and PMMA group was successfully evaluated in all directions in both the intact and instrumented specimens.

Mean (±SD) differences in stiffness were determined for specimens stabilized with the Uniplate and compared to those stabilized with self-tapping titanium cortical screws and PMMA in all directions (Table 1).

All surgical methods increased stiffness over the unaltered spine ($P < 0.001$). Stiffness of the Ti screw/PMMA fixation method was significantly greater than stiffness achieved with the Uniplate fixation method ($P < 0.001$) in all measurement directions. Stiffness was also significantly different among measurement direction—extension, flexion and right lateral bending ($P < 0.001$).

Radiographic Implant Assessment

Cortical ring allografts were seated within the borders of the endplates in all specimens. None of the Uniplate 2 screws penetrated the vertebral canal. Three of the specimens had radiographically apparent failure via fracture of the caudal endplate of C4. One of these specimens failed catastrophically in the first extension cycle, and further testing was not performed. One specimen exhibited pull-out of the caudal screw at the cranial endplate of C5 with an associated endplate fracture. One specimen appeared to have failure of the screw bone interface as it was grossly unstable during testing despite no radiographic evidence of fracture.

There was no radiographically apparent evidence of failure of the Ti screw/PMMA implants or bone after biomechanical testing. There was evidence of minimal canal penetration (<2 mm) with 1 of 36 screws.

DISCUSSION

We compared the mechanical properties of a monocortical screw/PMMA construct to that of the monocortical locking Uniplate 2 construct and found that the Uniplate 2 construct was biomechanically inferior to screw/PMMA constructs in cadaveric cervical vertebral column of dogs weighing 22 to 30kg. Additionally, we found that the Zero-P and Zero-P VA implants could not be applied to the cervical vertebral columns of dogs in this weight group.

In human medicine, use of plating for anterior cervical spine fusion is widespread.[18] Use of bicortical anterior screw fixation in anterior cervical fusion has fallen out of favor due to risks of neurologic compromise which lead to development of constrained cervical plates with locking mechanisms such as the Uniplate 2 system.[18] The Uniplate 2 design is unique in that it requires just one relatively large screw per vertebral level. This design is meant to address previously reported problems associated with use of two screws per vertebra in diseased or fractured vertebra, and backing out of small screws.[21] The Uniplate 2's small size also allows for its use in combination with other fixation methods such as cages, while reducing possibilities of dysphagia and/or recurrent nerve paralysis associated with large incisions with aggressive dissection and thermal injury from material such as PMMA.[21] Other benefits of one screw cervical plates (one screw/vertebral body plate=OSP) compared to the traditional two-screw/vertebral body plate (TSP) include a narrower profile, shorter operation time, and reduction of blood loss and damage to surrounding soft tissues while potentially maintaining the mechanical stability required after fusion procedures.[22] Possible downfalls of utilizing a single screw

per vertebrae versus 2 screws have been proposed, mainly that a single screw construct may not successfully resist motion as well as a 2 screw construct.[22-23]

Several studies in human medicine report biomechanical efficacy of OSP plates of similar design to the Uniplate 2.[19,22-24] One study evaluated the Uniplate™ (Depuy Spine, Raynham, MA, USA), an OSP similar to the Uniplate 2, and concluded that there was no significant difference between stiffness in specimens fixed with a OSP versus the traditional TSP.[19] An evaluation of constructs that utilize 1 screw per vertebral segment versus 2 screws found that, despite the theoretical stability provided by 2 screws, there was no significant biomechanical difference between the 2-screw plate and the 4-screw plates in flexion, extension, lateral bending and axial rotation up to 1.5 Nm.[23] Another biomechanical study determined that the Uniplate provides satisfactory stabilization (statistically insignificant difference) of cranial cervical spine intervertebral decompression in calf cadavers compared to the more traditional ORION Anterior Cervical Plate System® (Sofamor Danek, Memphis TN).[24] Finally, in a biomechanical comparison of various OSPs and TSPs, it was found that in lateral bending, the Uniplate had the largest increase in range of motion (ROM) (38% increase) of all plates tested, while one of the TSPs exhibited the smallest increase in ROM (10% increase).[22] This study proposed that the high ROM in lateral bending despite fixation may be due to lack of counter-rotation provided from a second point of fixation (i.e. second screw). While the overall performance of OSPs appears equivalent to that of TSPs in these biomechanical studies, cyclic or fatigue testing to examine long-term outcomes was not performed.

The results from our study in canine cadavers do not support the notion that monovertebral fixation with the Uniplate 2 system is biomechanically equivalent to multiple screw fixation in the canine cervical spine. Our findings are supported by other biomechanical studies in both human and veterinary literature. One study tested triangulated double-screw fixation compared to single-screw instrumentation in anterior spine surgery and found that fixation of the vertebra-device interface is substantially improved by application of the two triangulated screws.[25] Another study found that stiffness showed a significant linear increase with increasing number of monocortical screws in plate-rod fixation of canine femoral-gap ostectomy models.[26]

Furthermore, studies in human medicine demonstrate a high rate of complications in utilization of a OSP system. A case series of humans treated with the Uniplate for anterior cervical fusion demonstrate a high rate of symptomatic pseudarthrosis necessitating revision surgery compared to patients who were treated with a bivertebral screw plating system (4 of 13 cases (31%) versus 1 of 24 cases (4.4%), respectively).[18] Development of pseudarthrosis could not be evaluated in our cadaveric study but should be evaluated during prospective studies to determine how complication rates compare.

Size of the canine cervical disk spaces is a limiting factor when considering many human cervical interbody spacers for dogs. The small plate design of the Uniplate 2 and the dimensions of PEEK cages of the Zero-P implants appeared to make these implants applicable to the cervical vertebral column of large breed dogs. The Pit bull sized dogs used in this study are on the lower end of the weight spectrum of dogs typically affected

with CCSM. The weight range of 22-30kg was chosen to allow for direct comparisons between these human cervical implants and previously evaluated implants.[12]

The Zero-P and Zero-P VA were initially considered for biomechanical testing and comparison.[14,15] These implants combine a cervical interbody spacer and screw fixation through an integrated plate. While the 5mm parallel PEEK interbody spacers (smallest available) fit well within the confines of large breed canine disk spaces (Pit Bull terrier dogs), the cranially oriented locking screws could not engage the vertebral endplate due to the slant of the canine cervical disk space. As such, while the cages themselves were successfully used in dogs, neither the Zero-P nor Zero-P VA could be implanted stably. Among veterinary implants, the C-Lox device, which has been biomechanically evaluated, works with a similar distraction and fixation concept (disk spacer with incorporated screw fixation).[11]

All specimens in the Uniplate 2 group showed failure at the bone-screw interface, with the most common mechanisms of failure being fracture through the caudal aspect of the vertebral body/endplate of the cranial vertebra (Figure 3). A likely explanation for this mode of failure is the hourglass shaped anatomy of the canine cervical vertebral body, which creates a stress riser against the single locking screw. In the Uniplate 2 construct, the locking screws are relatively large compared to the diameter of the vertebral body, and may take up a larger percentage than the traditionally recommended 25% screw diameter to bone ratio.[27-29] Larger dogs may have increased vertebral body dimensions, which may decrease the risk of vertebral body fracture. -This, however, would have to be

evaluated by biomechanical studies utilizing larger breed dogs. None of the screws or plates showed macroscopic evidence of failure. As with other locking implants, failure of such constructs often occurs at the screw/bone interface via pull out of the bone or fracture.[30-33]

One large limitation of this study is that many of the specimens failed prior to the 4th cycle in extension, preventing consistency in the cycle used for statistical analysis. The high rate of failure in extension (the first direction tested) also precluded biomechanical evaluation of the Uniplate 2 in flexion and in lateral bending in most specimens. Even when flexion and lateral bending were evaluated, there was concern about compromise of the bone-implant interface and resultant effects on stiffness. We considered changing the order of testing to obtain potentially more valid stiffness values for the other directions. This, however, would have compromised comparison to the testing of the screw/PMMA constructs. Likewise, we considered lowering the load to prevent failure and allow us to test all 3 directions. Other veterinary biomechanical studies have much lower reported load settings but where also done with different testing setups.[8,10] To be able to directly compare the Uniplate 2 to the titanium screw/PMMA constructs, we decided to maintain the 150N load endpoint. Since the necessary stiffness of spinal implants is not known, an argument could be made that 150N is too high of a load. However, previous studies have used this load endpoint with other implants using the same testing setup without apparent bone/implant failure.[12, 20] Future studies should focus on larger dogs with increased vertebral dimensions, that are on the higher end of the size spectrum for CCSM, to

determine if these implants have improved performance (Uniplate 2) and improved ability of application (Zero-P, Zero-P VA).

Monocortical titanium screw/PMMA constructs using a cortical bone ring as spacer have been biomechanically evaluated in the canine cervical spine and compared to other implant constructs.[12] This construct allows non-constrained placement of individual screws and ability to adjust the screw insertion location and angle. They are also more cost effective than human cervical fusion plates. While the use of veterinary locking plates has been described for the use of canine cervical stabilization, these plates are not specifically designed for the canine cervical vertebral column.[5,8,13] Plate length and hole location must be carefully assessed for the individual dog, and the locking mechanism demands a specific screw orientation within the screw hole, which limits the versatility of screw orientation within the plate.

In conclusion, the results from this study indicate that both the Uniplate 2 and titanium screw/PMMA construct achieve a significant increase in stiffness compared to the unaltered spines. The Uniplate 2, however, is significantly less stiff compared to the screw/PMMA construct and led to bone/screw interface failure in all specimens. Although the data was obtained in an i*n vitro* model, which cannot fully predict *in vivo* biomechanical behavior, the human clinical implant cannot be recommended for use in Pit bull sized dogs at this time. Future studies should focus on biomechanical tests of both the Uniplate 2 and Zero-P implants in larger dogs, as increased vertebral bone stock may

allow for a decrease in vertebral fracture rate when using the Uniplate 2 and improved application of the Zero-P implants.

DISCLOSURE

The authors report no financial or other conflicts of interest related to this report.

REFERENCES

1. Trotter EJ: Cervical spine locking plate fixation for treatment of cervical spondylotic myelopathy in large breed dogs. *Vet Surg* 2009;38:705–718

2. Queen JP, Coughlan AR, May, C et al: Management of disc-associated wobbler syndrome with a partial slot fenestration and position screw technique. *J Small Anim Pract* 1998;39:131-136

3. Jeffrey ND and McKee W: Surgery for disc-associated wobbler syndrome in the dog- an examination of the controversy. *J Small Anim Pract* 2001;42:574-581

4. Sharp N, Wheeler S: Cervical spondylomelopathy, in Wheeler S (ed): Small Animal Spinal Disorders, Diagnosis and Surgery (ed 2). Edinburgh, Elsevier Mosby, 2005, pp 211–246

5. Voss K, Steffen F, Montavon PM: Use of the ComPact unilock system for ventral stabilization procedures of the cervical spine. *Vet Comp Orthop Tramatol* 2006;19: 21–28

6. Bruecker K, Seim HB, Withrow S: Clinical evaluation of three surgical methods for treatment of caudal cervical spondylomyelopathy of dogs. *Vet Surg* 1989;18:197–203

7. Dixon B, Tomlinson J, Kraus K: Modified distraction-stabilization techniques using

an interbody polymethyl methacrylate plug in dogs with caudal cervical spondylomyelopathy. *J Am Vet Med Assoc* 1996;208:61–68

8. Solano MA, Fitzpatrick N, Bertran J: Cervical distraction-stabilization using an intervertebral spacer screw and string-of pearl (SOPTM) plates in 16 dogs with disc-associated wobbler syndrome. *Vet Surg* 2015;44:627-41

9. Steffen F, Voss K, Morgan JP: Distraction-fusion for caudal cervical spondylomyelopathy using an intervertebral cage and locking plates in 14 dogs. *Vet Surg* 2011;40:743–752

10. Bergman RL, Levine JM, Coates JR et al: Cervical spinal locking plate in combination with cortical ring allograft for a one level fusion in dogs with cervical spondylitic myelopathy. *Vet Surg* 2008;37:530-536

11. Schöllhorn B, Bürki A, Stahl C, et al: Comparison of the biomechanical properties of a ventral cervical intervertebral anchored fusion device with locking plate fixation applied to cadaveric canine cervical spines. *Vet Surg* 2013;42:825-831

12. Hettlich BF, Allen MJ, Pascetta D, et al: Biomechanical comparison between bicortical pin and monocortical screw/polymethylmethacrylate constructs in the cadaveric canine cervical vertebral column. *Vet Surg* 2013;42:693-700

13. Agnello KA, Kapatkin AS, Garcia TC, et al: Intervertebral biomechanics of locking compression plate monocortical fixation of the canine cervical spine. *Vet Surg* 2010;39:991-1000

14. DePuy Synthes Spine: Zero-P and Zero-P chronOS. Zero profile anterior cervical interbody fusion (ACIF) device. *Synthes Technique Guide*; 1-69

15. DePuy Synthes Spine: Zero-P VA Variable angle zero-profile anterior cervical interbody fusion (ACIF) device. *Synthes Technique Guide* 2013; 1-44

16. Wojewnik B, Ghanayem AJ, Tsitsopoulos PP, et al: Biomechanical evaluation of a low profile, anchored cervical interbody spacer device in the setting of progressive flexion-distraction injury of the cervical spine. *Eur Spine J* 2013;22:135-141

17. Lee Y, Kim, Y and Park, S: Does a zero-profile anchored cage offer additional stabilization as anterior cervical plate? *Spine* 2015;40:63-70

18. Dumont TM, Lin CH, Tranmer BI, et al: Pseudarthrosis failures of anterior subaxial cervical spine fusion using a plate with a single screw per vertebral body: a case series. *World Neurosurg* 2014;82:225-230

19. Fassett DR, Csaszar DJ, Albert TJ: Anterior cervical plating update. *Curr Opin Orthop* 2007;18:282-288

20. Hettlich BF, Allen MJ, Glucksman GS, et al. Effect of an intervertebral disk spacer on stiffness after monocortical screw/polymethylmethacrylate fixation in stimulated and cadaveric canine cervical vertebral columns. *Vet Surg* 2014;1-7

21. Lin PS: United States Patent Application Publication: Uniplate Cervical device 2004;1-6

22. Hunter W, Bucklen B, Muzumdar A, et al: A comparative biomechanical study of traditional and in-line plating systems following immediate stabilization of single and bi-level cervical segments. *Clin Biomech* 2012;27:84-90

23. Crawford N, Scholz M, Reyes PM, et al. Biomechanics of one-level anterior cervical discectomy and plating using two screws versus four screws. *Spine J* 2011;11:234-240

24. Zhang F, Lu J, Zhao J, et al. Uniplate with the Orion anterior cervical plate fixation biomechanics single gap study. *Chin J Orthop Surg* 2008;16:1490–2

25. Ogon M, Krismer C, Sterzinger M, et al: Comparison between single-screw and triangulated, double-screw fixation in anterior spine surgery: A biomechanical test. *J OrthopTrauma* 2003;18:488-493

26. Delisser PJ, McCombe GP, Trask RS, et al: Ex vivo evaluation of the biomechanical effect of varying monocortical screw numbers on a plate-rod canine femoral gap model. *Vet Comp Orthop Traumatol* 2013;3:177-185

27. Poitout DG: Biomaterials used in orthopedics. in Poitout DG (ed): *Biomechanics and biomaterials in orthopedics.* London, UK, Springer, 2004,15–21

28. Johnson AL, Houlton JEF, Vannini R: Implants and materials in fracture fixation. in *AO principles of fracture management in the dog and cat.* Davos Platz, Switzerland, AO Publishing, Stuttgart, Germany, Thieme, 2005;477–487

29. Toombs JP: Fractures of the radial diaphysis. in *AO principles of fracture management in the dog and cat.* Davos Platz, Switzerland, AO Publishing, Stuttgart, Germany, Thieme, 2005;236-251

30. Malenfant RC and Sod GA: In vitro biomechanical comparison of 3.5 string of pearl plate fixation to 3.5 locking compression plate fixation in a canine fracture gap model. *Vet Surg* 2014;43:465-470

31. Schneider K, Oh J, Zderic, I et al: What is the underlying mechanism for the failure mode observed in the proximal femoral locking compression plate? A biomechanical study. *Injury* 2015;46:1483-90

32. Forward DP, Doro CJ, O'Toole, RV et al: A biomechanical comparison of a locking plate, a nail, and a 95º angled blade plate for fixation of subtrochanteric femoral fractures. *J Orthop Trauma* 2012;26:334-340

33. Thapa N, Prayson M and Goswami T: A failure study of a locking compression plate implant. *Case Stud Eng Fail Anal* 3 2015:68-72

FIGURE LEGENDS

Figure 1. Photographs of each implant in ventral and axial views (middle and right) and showcasing individual components (left).

Figure 2. Lateral and ventrodorsal radiographic projections of canine C4–C5 vertebrae instrumented with 3 human cervical fusion implants. A: Zero-P with PEEK interbody cage, titanium interbody plate and four 2.4mm stainless steel locking screws. B: Zero-P VA with PEEK interbody cage, titanium interbody plate and two self-drilling 3.7mm variable angle titanium screws. C: Uniplate 2 with cortical ring disk spacer and 2 self-drilling 4.6mm titanium screws locked using the CAM-LOC.

Figure 3.

Lateral radiographic projections of C4-C5 vertebrae demonstrating 2 types of implant failures after testing of the Uniplate 2/cortical ring constructs. A: pullout of the caudal screw with a fracture in the cranial endplate of C5. B: fracture of the caudal endplate of C4.

Table 1 Absolute mean (±SD) differences in stiffness from pre- to post-fixation for Uniplate 2 versus Ti screw/PMMA [% of specimens successfully tested]

Fixation method	Extension (N/mm)	Flexion (N/mm)	Right Lateral Bending (N/mm)
Uniplate 2	115.08 (47.09) [100%]	61.72 (17.93) [50%]	18.79 (10.31) [50%]
Ti screw/PMMA	137.06 (4.10) [100%]	313.6 (83.52) [100%]	327.76 (64.21) [100%]

Photographs of each implant in ventral and axial views (middle and right) and showcasing individual components (left).
1321x1060mm (96 x 96 DPI)

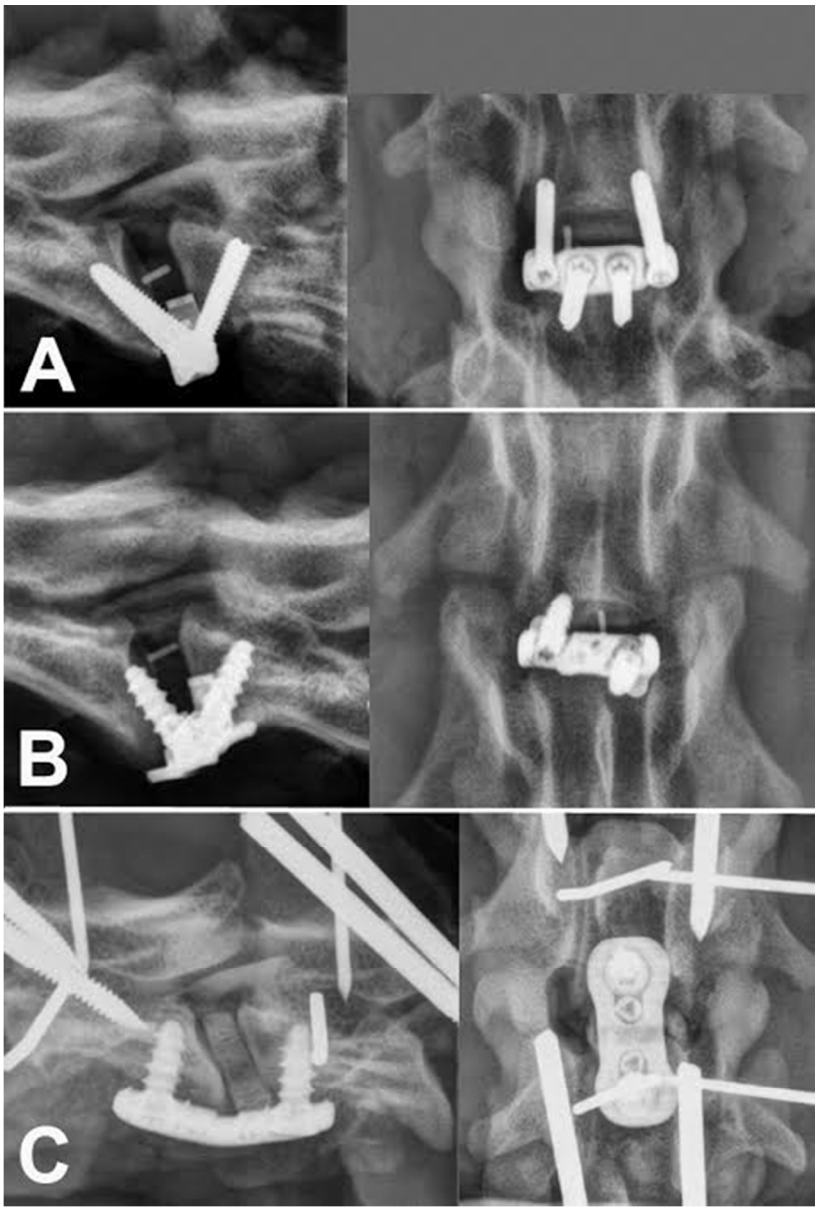

Lateral and ventrodorsal radiographic projections of canine C4–C5 vertebrae instrumented with 3 human cervical fusion implants. A: Zero-P with PEEK interbody cage, titanium interbody plate and four 2.4mm stainless steel locking screws. B: Zero-P VA with PEEK interbody cage, titanium interbody plate and two self-drilling 3.7mm variable angle titanium screws. C: Uniplate 2 with cortical ring disk spacer and 2 self-drilling 4.6mm titanium screws locked using the CAM-LOC.
168x249mm (72 x 72 DPI)

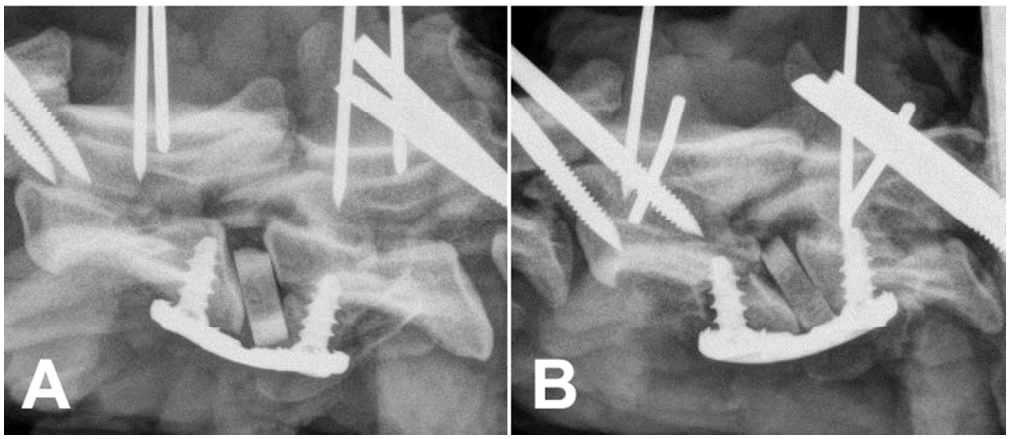

Lateral radiographic projections of C4-C5 vertebrae demonstrating 2 types of implant failures after testing of the Uniplate 2/cortical ring constructs. A: pullout of the caudal screw with a fracture in the cranial endplate of C5. B: fracture of the caudal endplate of C4.
218x93mm (96 x 96 DPI)